

RESEARCH ARTICLE

Electrocardiography in Conscious Releasable Andean Condors (*Vultur gryphus*): Reference Panel and Unusual Findings

Guillermo M. Wiemeyer,^{1,2*} Sergio A. Lambertucci,³ Laura Torres Bianchini,^{1,2} and Guillermo Belerenian⁴

¹Jardín Zoológico de la Ciudad de Buenos Aires, Rep. de la India 3000 (CP 1425), Ciudad Autónoma de Buenos Aires (CABA), Argentina

²Facultad de Ciencias Veterinarias, Universidad de Buenos Aires, CABA, Argentina

³Laboratorio Ecotono, INIBIOMA (Universidad Nacional del Comahue-CONICET), Bariloche, Argentina

⁴Instituto Nacional de Zoonosis Luis Pasteur, CABA, Argentina

Electrocardiography is a useful tool when included in healthcare protocols and is increasingly utilized for monitoring wild birds. However, the lack of reference data for many species is limiting the clinical value of this technique. In this study 26 Andean condors (*Vultur gryphus*) coming from rehabilitation and captive breeding programs were examined to determine electrocardiographic references prior to being released. Standard bipolar (I, II, and III) and augmented unipolar limb (aVR, aVL, and aVF) leads were recorded with birds under physical restraint. Five beats were analyzed on Lead II at 50 mm/sec and 1 cm = 1 mV to determine QRS complex morphology, cardiac rhythm, heart rate, P, PR, R, S, QRS, T, QT, and ST amplitude and/or duration. P and T wave configuration was determined for all leads, and Mean Electrical Axis (MEA) in the frontal plane was determined using leads I and III. Cardiac rhythm corresponded to regular sinus rhythm in 42% of the birds, with a relevant rate of sinus arrhythmia in 58%, and rS as the most common pattern (42%) for QRS complex in lead II. We found an influence of age and heart rate but not of sex on several ECG waves and intervals. Relevant ECG findings for studied Andean condors include a high rate of T_a, R', and U wave detection. Waves T_a and R' were considered non-pathological, while the significance of U waves remains unclear. Our results provide a useful reference to improve clinical interpretation of full electrocardiographic examination in Andean condors. Zoo Biol. 32:381–386, 2013. © 2013 Wiley Periodicals Inc.

Keywords: avian cardiology; electrocardiogram; ECG; scavenger; condor

INTRODUCTION

Electrocardiography (ECG) is a well-established method for cardiac function evaluation and monitoring in human and avian patients [Pérez Riera et al., 2008; Hassanpour et al., 2010]. Widely used to diagnose cardiac arrhythmias and conduction disturbances, it can also detect chamber enlargement. The first reports on avian electrocardiography date back to the early twentieth century [Buchanan, 1909; Kahn, 1915], but it was after the 1950s that investigations focused on domestic species for commercial purposes [Sturkie, 1949; McKenzie et al., 1971]. During the 1990s, as companion birds medicine became more popular, ECG started being applied clinically in companion bird species, including psittacines, pigeons, and falconry birds [Burtneck and Degernes, 1993; Cinar et al., 1996; Martinez et al., 1997; Oglesbee et al., 2001; López Murcia et al., 2005]. Electrocardiography is increasingly utilized in

wild birds, but the lack of reference data for many species is probably limiting its clinical value and/or the interpretation of data obtained through this technique.

Captive and free-ranging wild birds are frequently admitted to veterinary hospitals or rehabilitation centers for

Additional supporting information may be found in the online version of this article.

The authors have no conflict of interest to declare.

*Corresponding to: Dr. Guillermo M. Wiemeyer, Rep. de la India 3000 (CP 1425), Ciudad Autónoma de Buenos Aires (CABA), Argentina. E-mail: gwiemeyer@zoobuenosaires.com.ar; gwiemeyer@gmail.com

Received 20 January 2012; Revised 29 November 2012; Accepted 18 December 2012

DOI 10.1002/zoo.21060

Published online 5 February 2013 in Wiley Online Library (wileyonlinelibrary.com).

medical attention due to infectious or non-infectious disease (like trauma, electrocution or intoxications). Birds often present with nonspecific clinical signs, some of which can be related to primary and secondary cardiac disease [Talavera et al., 2008]. In these cases, ECG may detect not only primary heart diseases but several subsequent abnormalities related to infectious and noninfectious diseases [Espino et al., 2001]. West Nile virus can cause cardiac and pericardial lesions [Eidson et al., 2001], and *Staphylococcus* sp. (secondary to pododermatitis) can produce bacteremia and endocarditis [Berners, 2002]. Using ECG, secondary heart compromise has been documented in birds suffering a range of conditions, including influenza [McKenzie and Will, 1972] Newcastle disease [Mitchell and Brugh, 1982], thiamine deficiency [Sturkie, 1952], and hyperkalemia [Andersen, 1975]. To the authors' knowledge an association between lead exposure and secondary cardiovascular disease in birds has not been described. However, considering this has been documented in humans [Navas-Ancien et al., 2007], lead exposed raptors should be investigated for secondary cardiovascular disease.

Clinical application of electrocardiography has been described in European [Edjehadi et al., 1977; Espino et al., 2001; Rodríguez et al., 2004; Talavera et al., 2008] and American raptor species [Burnick and Degernes, 1993; Hassanpour et al., 2010]. In vultures, ECG has been reported predominantly as an indirect tool to assess energy expenditure [Prinzinger et al., 2002; Mandel et al., 2008] or heart rate changes in response to selected stimuli [Smith and Paselk, 1986].

The Andean Condor (*V. gryphus*) is the largest South American scavenger [del Hoyo et al., 1994]. It is a sexually dimorphic species, with males being up to 30% larger than females [del Hoyo et al., 1994]. It inhabits the Andes Mountains, and it is threatened mostly in the north of its range, being considered as Near Threatened [Birdlife International, 2012]. Condors spend most of their time soaring within thermal currents, reaching heights of 5,000 m in mountain regions, and feed mostly at ground level in open grasslands [del Hoyo et al., 1994; Carrete et al., 2010; Shepard et al., 2011]. Consequently, the cardiovascular system of the condor is required to adjust cardiac output and blood pressure in response to extremes of altitude, pressure, and physical activities, as a consequence of this landscape use. Previous investigations have shown cardiovascular adaptive fitness for certain bird species living in extreme environments or making specially challenging migrations [e.g., *Anser indicus*, Hawkes et al., 2011].

Cardiac abnormalities include degenerative vascular pathologies like atherosclerosis that have been reported in the Andean condor [Finlayson, 1965] and Egyptian Vulture [*Neophron percnopterus*, Grünberg and Kaiser, 1965; Grünberg and Kaiser, 1966]. Andean condors are sensitive to lead poisoning [Pattee et al., 2006] and detectable lead levels had been reported for free-ranging condors in Argentina [Lambertucci et al., 2011]. Considering lead induces changes in cardiac electrophysiology and neural conduction

[Navas-Ancien et al., 2007], ECG abnormalities may be presented in association to that environmental toxicosis.

The purpose of this study was to obtain electrocardiographic reference data in conscious releasable Andean condors. This will improve the medical management of both captive and free ranging populations of this threatened species and forms a basis for further investigation of vulture cardiology.

MATERIALS AND METHODS

We studied Andean condors coming from rehabilitation and ex situ captive breeding programs between April 2008 and November 2010. Sex and age were determined according to external sexual dimorphism and feather pattern [del Hoyo et al., 1994; Lambertucci, 2010]. We studied 26 condors: seven adult and six immature males, and seven adult and six immature females. Birds came from different locations across Argentina, and were temporarily maintained at the Buenos Aires Zoo, Argentina.

Captive reared birds were examined between day 180 and 240 post-hatching. Birds undergoing rehabilitation were in care for an average of 2 months. The most frequent presentations at admission were poor body condition, dehydration, and trauma. Cardiac function was evaluated using ECG in order to determine basic cardiovascular fitness as part of a complete pre-release assessment protocol including hematology, biochemistry, bacteriology, and radiology. Electrocardiograms were used only in those cases when laboratory results supported the good body condition verified during clinical examination.

Birds were fasted for 24 hr prior to examination, and were captured by hand net. Condors were blindfolded using cotton towels, weighed, and restrained manually in dorsal recumbency. All cardiac tracings were obtained in a quiet place between 10:00 and 13:00 hr using both a Cardiotécnica 301 single channel (Cardiotécnica SRL, Buenos Aires, Argentina), and 3-channel Fukuda (Turco-Belerman Equipment SRL, Buenos Aires, Argentina) electrocardiographs. Alligator clip electrodes were attached to the propatagium of the left and right wing, and to the inguinal skin fold of the left and right legs. Application of 96% ethanol facilitated parting of feathers and good clip-to-skin contact. Standard bipolar (I, II, and III) and augmented unipolar limb (aVR, aVL, and aVF) leads were recorded using 25 and 50 mm/sec paper speed and 1 cm = 1 mV or 2 cm = 1 mV. Configuration of P and T waves were determined for all leads. QRS morphology, cardiac rhythm, and waves measurements were manually determined for five beats on lead II at 50 mm/sec and 1 cm = 1 mV, and mean electrical axis in the frontal plane was determined using leads I and III [Tilley, 1992].

Potential influences of sex, age, and heart rate on ECG measures were evaluated through generalized linear models (GLM; Normal Distribution; when necessary we log-transformed the data). For this, we built a model including sex, age, and heart rate as explanatory variables and the ECG

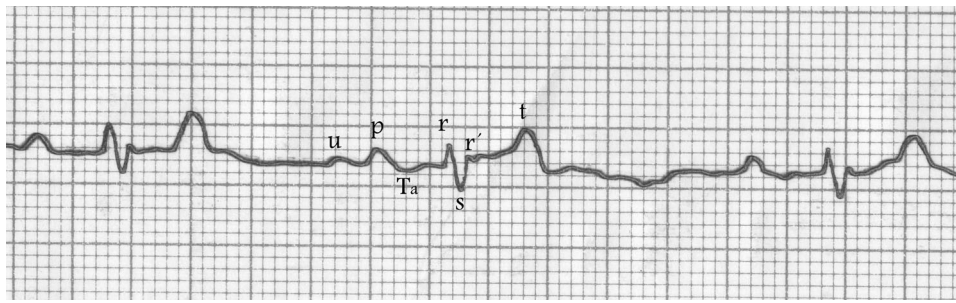


Fig. 1. Atypical deflections documented in Andean condor electrocardiogram, Lead II, amplitude 1 mv = 1 cm, 50 mm/seg speed.

parameters as the dependent variable. Statistical assumptions of the model were met.

RESULTS

Physical restraint of conscious condors resulted in good quality tracings for 25 and 50 mm/sec and 1 cm = 1 mV amplitude (see Lead II in Fig. 1; see other leads in Supplementary Material Fig. S1). Tracings at 2 cm = 1 mV resulted in magnified artifacts and were not used.

The weight of the 20 birds weighted ranged from 7 to 12 kg with a mean (\pm SD) of 9.290 ± 0.158 kg. The heart rate of those birds was highly variable (mean 162.7 ± 41.04 beats/min; range 120–240 beats/min). Cardiac rhythm corresponded to regular sinus rhythm in 42% (11/26) of the birds, with a relevant rate of sinus arrhythmia in 58% (15/26). No other rhythm alteration was detected, except for one occasional sinus arrest. Polarity of P and T waves were similar in most leads, with morphology tending to be positive in leads I, II, III, and aVF, and negative in aVR (see Table 1); configuration differed substantially in aVL with P waves predominantly positive, and T waves either positive or negative configuration in equal proportion (Table 1).

Amplitude and duration measures and reference intervals including 95% CI are shown in Table 2. In Lead II, we detected deflections that did not correspond to any of the waves usually reported in wild birds. Interference and occasional artifacts were discarded because those waves were present in at least four of the five analyzed beats for each bird (Fig. 1). The first atypical deflection characterized was a slight depression registered at the beginning of the PR

interval, classified as a Ta wave, corresponding to a definite auricular T wave (Fig. 1). It was present in 15/26 condors (58%) for lead II (Table 3). The second was a positive deflection classified as a U wave. Even though this wave is not present for all species or individuals, it is described as a positive deflection posterior to the T wave and previous to the P wave. We found a positive U wave in 54% (14/26) of the condors (Table 3). When present, it was always detectable in lead II, and occasionally in other leads. The last wave documented was a second positive deflection in the lead II QRS complex, registered immediately after S. It was classified as R' wave (Fig. 1) and was detected in 12/26 (46%) condors (Table 3).

Due to substantial variation, QRS morphology was characterized only for lead II (Table 3). We did not register Q waves. The most common configuration for lead II was rS (42%; 11/26), followed by rSr' (31%; 8/26) and RSr' (23%; 6/26). Only one specimen of the 26 condors (4%) showed an RS configuration. The ST segment was present in all tracings, being elevated over the baseline in 19/26 cases (73%), isoelectric in two cases (8%) and negative in the remaining five birds (19%). We did not detect any ST slurring.

The models considering the influence of sex, age, and heart rate on the ECG showed that both age and heart rate (HR) significantly influenced several ECG parameters' duration and amplitude (Table 4). However, the sex did not influence strongly any ECG parameter, except, marginally, the P wave duration. Juvenile condors tended to have shorter PR, QRS, and QT intervals, and smaller P waves (voltage). Higher heart rate resulted in shorter P, PR, and ST waves, but T wave amplitude increased with HR (Table 4).

TABLE 1. P and T wave configuration for standard bipolar and augmented limb leads in ECG from conscious Andean condors destined for release

Configuration		DI	DII	DIII	aVR	aVL	aVF
P wave	Positive	100% (26/26)	100% (26/26)	77% (20/26)	04% (1/26)	58% (15/26)	100% (26/26)
	Negative	0	0	19% (5/26)	96% (25/26)	23% (6/26)	0
	Isobiphasic	0	0	04% (1/26)	0	19% (5/26)	0
T wave	Positive	100% (26/26)	96% (25/26)	96% (25/26)	23% (6/26)	50% (13/26)	88% (23/26)
	Negative	0	0	04% (1/26)	77% (20/26)	50% (13/26)	04% (1/26)
	Isobiphasic	0	04% (1/26)	0	0	0	08% (2/26)

TABLE 2. Reference values for waves and intervals in conscious releasable Andean condors

Parameter	Units	Mean \pm SD	Range	Median	Confidence interval (95%)
P	Ms	46 \pm 8	32–60	46	43–49.4
	mV	0.162 \pm 0.051	0.01–0.24	0.162	0.141–0.1826
R	Ms	18 \pm 35	10–22.5	18	17–19.7
	mV	0.144 \pm 0.094	0.05–0.48	0.144	0.106–0.1818
PR	Ms	47.5 \pm 15.4	30–88	48	41–53.8
QRS	Ms	48.1 \pm 4.9	40–60	48	46–50.1
S	Ms	29.4 \pm 3.9	22–40	29	28–30.9
	mV	0.44 \pm 0.21	0.14–0.82	0.437	0.352–0.5216
R'	Ms	10.5 \pm 2.8	6–16	10	9–12.3
	mV	0.06 \pm 0.04	0.03–0.17	0.064	0.040–0.885
ST	Ms	50 \pm 10	32–76	59	53–64.2
	mV	0.033 \pm 0.037	–0.02 to 0.1	0.033	0.018–0.048
T	Ms	67 \pm 9	48–76	67	63–70.3
	mV	0.297 \pm 0.189	0.05–0.77	0.297	0.018–0.048
QT	Ms	173.6 \pm 17.9	136–205	173	166–180.8

TABLE 3. Selected waves incidence and QRS pattern for Lead II in Andean condors

Ta	Waves' incidence			QRS pattern			
	r'	U		rS	rSr	RSr'	RS
58%	46%	54%		42%	31%	23%	4%
(15/26)	(12/26)	(14/20)		(11/26)	(8/26)	(6/26)	(1/26)

Mean electrical axis in the frontal plane was always negative and cranially directed. It ranged widely from -23° to -150° with an average of $-103^\circ + 26.36^\circ$.

DISCUSSION

We performed electrocardiograms on Andean condors otherwise considered healthy and fit for release. These results can be considered as references measures for condors in short-term captivity. Moreover, we provide the first report on

unexpected electrocardiographic findings like Ta, R', and U waves possibly common in Andean condors.

The Ta wave is associated with large atrial repolarization forces. It has been attributed to atrial hypertrophy in other species, notably dogs [Tilley, 1992], but it is considered a normal finding for racing pigeons [Lumeij and Stokhof, 1985] and some gallinaceous birds [Boulianne et al., 1992]. In parrots it is occasionally noted [Nap et al., 1992] but it has never been reported for raptors. Given that this is a common result for other avian species and that we did

TABLE 4. Influence of heart rate (HR), sex, and age of Andean condors in the ECG waves and intervals

Waves	HR				Sex				Age			
	Estimate	Lower CL 95%	Upper CL 95%	P-value	Estimate	Lower CL 95%	Upper CL 95%	P-value	Estimate	Lower CL 95%	Upper CL 95%	P-value
P (seg)	-0.002	-0.00284	-0.00023	0.022	0.050	-0.00287	0.10279	0.064	-0.041	-0.09144	0.00985	0.114
PR (seg)	-0.003	-0.00542	-0.00125	0.002	-0.017	-0.10139	0.06658	0.685	-0.133	-0.21231	-0.05275	0.001
QRS (seg)	<-0.001	-0.00116	0.00069	0.619	0.008	-0.02932	0.04537	0.674	-0.036	-0.07170	-0.00076	0.045
S (seg)	<-0.001	-0.00131	0.00120	0.934	-0.025	-0.07552	0.02581	0.336	-0.026	-0.07448	0.02177	0.283
ST (seg)	-0.003	-0.00494	-0.00109	0.002	-0.022	-0.09930	0.05487	0.572	-0.061	-0.13595	0.01360	0.109
QT (seg)	-0.001	-0.00163	0.00005	0.067	-0.009	-0.04378	0.02576	0.611	-0.047	-0.08071	-0.01425	0.005
P (mv)	<-0.001	-0.00298	0.00224	0.783	0.056	-0.06105	0.17306	0.348	-0.126	-0.23880	-0.01383	0.028
ST (mv)	-0.006	-0.0154	0.00285	0.178	-1.398	-41.1734	38.37716	0.945	1.608	-38.1672	41.38338	0.937
T (mv)	0.007	0.00221	0.01269	0.005	0.118	-0.09482	0.33014	0.278	-0.196	-0.40001	0.00796	0.060

Significant differences ($P \leq 0.05$) are indicated by bold text; CL, confidence limits.

not detect other electrocardiographic signs of right atrial hypertrophy (in forms of tall P waves), we consider the Ta wave might be normal in condors.

In lead II, 44% of the birds had a second positive deflection after R, defined as r' wave. This has not been reported in raptors or any other avian species. The clinical significance of this wave in the avian electrocardiogram is still unknown. It has only been documented previously in humans [Mirvis and Goldberger, 2007] with both right ventricular hypertrophy and intraventricular conduction abnormalities (i.e., right bundle branch block, RBBB). The r' wave can extend the QRS interval, widening the QRS and can sometimes result in an rSR' pattern for precordial leads V1 and V2. In these cases, r' waves are generally large and prolonged. Although in humans RBBB is generally considered to be an alteration of intraventricular conduction, it is commonly found in healthy individuals without clinical significance [Mirvis and Goldberger, 2007]. We detected r' waves in lead II with small amplitude and short duration, sometimes even shorter and smaller than the first r wave. The use of precordial leads V1–V6 has not been previously reported in birds. Thus, as these leads were not included in this study, r' presence in leads V1 and V2, as in humans, could not be verified. We found neither prolonged QRS, nor other signs of abnormal intraventricular conduction, and thus cannot attribute pathology to rSR' patterns in Andean condors.

This study is the first record of a positive U wave, which was present in approximately half (55%) of the condors. This is the only waveform in the electrocardiogram whose genesis remains controversial. Four major theories have been postulated in humans [Pérez Riera et al., 2008; Schimpf et al., 2008]: (1) repolarization of the intraventricular conducting system or Purkinje fibers system; (2) delayed repolarization of the papillary muscles; (3) after potentials caused by mechano-electrical hypothesis-mechano-electrical feedback; and (4) the prolonged repolarization of the mid-myocardium cells ("M-cells"). In humans, a negative U wave in some precordial leads is highly specific for the presence of heart disease and is often associated with other ECG abnormalities [Pérez Riera et al., 2008]. Even though the clinical significance of, U waves is well recognized for humans [Kishida et al., 1982], it has been reported as a normal finding for some avian species, including quails [Szabuniewicz and McCrady, 1974]. Previous reports indicate that many birds tend to show easily detectable U waves, with the amplitude comparable to humans [Lepeschkin et al., 1957]. The presence of this wave was not related to other detectable ECG abnormalities in studied condors, and its significance is unclear. Therefore, further studies are encouraged to determine if this is a normal or a pathological finding for Andean condors.

The use of proper physical restraint by trained personnel allowed obtaining good quality ECG tracings. Besides the effort to reduce stressors during the birds manipulation, individual susceptibility to handling stress may have resulted in a differential increase of heart rate, increasing variability of measures, and influencing some other ECG

deflections. Anesthetizing the birds may have facilitated lower stress levels, but we decided to work with conscious condors because previous reports indicate that data obtained from animals undergoing sedation or anesthesia should not be extrapolated to conscious animals [Miller, 1986; Tilley, 1992; Lumeij and Ritchie, 1999]. Moreover, electrocardiographic alterations have been associated with anesthesia in raptors [Aguilar et al., 1995]. In addition, it is not always possible to anesthetize wild birds during field work, due to logistical limitations, large numbers of individuals captured, or the absence of qualified personnel. Extrapolating data obtained under general anesthesia may not be valid for conscious free-ranging birds.

There exist differences in the morphology and behavior between the different condors sexes and ages, and hence in the conservation of this species [del Hoyo et al., 1994; Lambertucci et al., 2012]. We did not find clear influence of the sex in any of the ECG waves studied, although the sample size might be influencing our results. However, our results suggest that age and heart rate should be considered when interpreting electrocardiographic data. Excluding the positive relationship between heart rate and T wave amplitude, the negative association between heart rate and many ECG deflections agrees with previous findings for raptors [Espino et al., 2001; Talavera et al., 2008]. The MEA range in condors was closely related to the Griffon Vultures [*Gyps fluvius*, Talavera et al., 2008], but mean values were quite different, probably due to different sample size. Talavera et al. [2008] reported a negative correlation between HR and body weight for anesthetized vultures. For Andean condors, we did not evaluate possibly correlation between body weight and heart rate, nor the influence of BW on ECG results. This was because of incomplete body weight data, and the potential variability due to manual restraint could confound such interpretation.

CONCLUSIONS

Here we present the first reference database of ECG values for *Vultur gryphus*, contributing to a better understanding of its cardiovascular physiology, and widening the possibilities to use electrocardiography as a diagnostic tool for both clinical investigation and conservation purposes. Considering the lack of information about Andean condor cardiology, together with the finding of unusual waves in this species, further investigations are encouraged to determine if any other particularities are present in this species' cardiovascular system. Future applications of our results include not only diagnosing primary heart disease in Andean condors, but detecting secondary electrocardiographic changes related to metabolic disorders, or infectious and non-infectious diseases.

ACKNOWLEDGMENTS

This research was supported by Buenos Aires Zoo. Studied condors were enrolled in the Bi-national Argentina-Chile Andean Condor Conservation Program, and we thank

N.L. Jácome and V. Astore for entrusting the birds' medical care to Buenos Aires Zoo Veterinary Staff. We are indebted to zoo keepers for assistance during animal handling and with Bioandina Argentina Foundation staff and volunteers for aid in daily care of the condors. We thank the comments of two anonymous reviewers and of J. Lemus on an earlier version of this manuscript.

REFERENCES

- Aguilar RF, Smit VE, Ogbur P, Redig PT. 1995. Arrhythmias associated with isoflurane anesthesia in bald eagles (*Haliaeetus leucocephalus*). *J Zoo Wildl Med* 26:508–516.
- Andersen HT. 1975. Hyperpotassemia and electrocardiographic changes in the duck during prolonged diving. *Acta Physiol Scand* 63:292–295.
- Berners JD. 2002. Foot conditions. In: Cooper JE, editor. *Birds of prey: health and disease*, 3rd Ed. Oxford, UK: Blackwell Science Ltd. p 122–131.
- Bird Life International. 2012. Species factsheet: vultur gryphus. <http://www.birdlife.org> (accessed August 10, 2012).
- Boulianne M, Hunter DB, Julian RJ, O'Grady MR, Physick-Sheard PW. 1992. Cardiac muscle mass distribution in the domestic turkey and relationship to electrocardiogram. *Avian Dis* 36:582–589.
- Buchanan F. 1909. The frequency of the heart-beat and the form of the electrocardiogram in birds. *J Physiol* 38:62–66.
- Burnnick NL, Degernes LA. 1993. Electrocardiography on fifty-nine anesthetized convalescing raptors. In: Redig PT, Cooper JE, Remple JD, Hunter DB, editors. *Raptor biomedicine*. Minneapolis, USA: University of MN Press. p 111–121.
- Carrete M, Lambertucci SA, Speziale K, Ceballos O, Travaini A, Delibes M, Hiraldo F, Donazar JA. 2010. Winners and losers in human-made habitats: interspecific competition outcomes in two Neotropical vultures. *Animal Conserv* 13:390–398.
- Cinar A, Bagci C, Belge F, Uzunet M. 1996. The electrocardiogram of the pekin duck. *Avian Dis* 40:919–923.
- del Hoyo J, Elliott A, Sargatal J. 1994. *Handbook of the birds of the world. Volume 2: new world vultures to guinea fowl*. Barcelona, España: Lynx Edicions.
- Edjtehadi M, Rezakhani A, Szabniewicz M. 1977. The electrocardiogram of the buzzard (*Buteo buteo*). *J Vet Med A* 24:597–600.
- Eidson ML, Kramer L, Stone W, Hagiwara Y, Schmit K. The New York State West Nile Virus Avian Surveillance Team. 2001. Dead bird surveillance as an early warning system for West Nile Virus. *Emerg Infect Dis* 7:631–636.
- Espino L, Suárez M, López-Beceiro A, Santamarina G. 2001. Electrocardiogram reference values for the Buzzard in Spain. *J Wildlife Dis* 37:680–685.
- Finlayson R. 1965. Spontaneous arterial disease in exotic animals. *J Zool* 147:239–343.
- Grünberg W, Kaiser E. 1965. Spontaneous arteriosclerosis in a population of free-living Egyptian vultures (*Neophron percnopterus*). I. Prevalence, morphology and evolution of lesions. *Acta Cardiol* 11:189–205.
- Grünberg W, Kaiser E. 1966. Spontaneous arteriosclerosis in a population of free-living Egyptian vultures (*Neophron percnopterus*). II. Histochemistry of lesions and chemical analysis of aortic tissue and blood serum. *Acta Cardiol* 21:446–456.
- Hassanpour H, Zamani Moghaddam AK, Cheraghchi Bashi M. 2010. The normal electrocardiogram of conscious golden eagles (*Aquila chrysaetos*). *J Zoo Wildl Med* 41:426–431.
- Hawkes LA, Balachandran S, Batbayar N, et al. 2011. The trans-Himalayan flights of bar-headed geese (*Anser indicus*). *Proc Natl Acad Sci USA* 108:9516–9519.
- Kahn RH. 1915. Das Vogel-Ekg. *Arch Gesamte Physiol* 162:67–93.
- Kishida H, Cole JS, Surawicz B. 1982. Negative U wave: a highly specific but poorly understood sign of heart disease. *Am J Cardiol* 49:2030–2036.
- Lambertucci SA. 2010. Size and spatio-temporal variations of the Andean condor Vultur gryphus population in north-west Patagonia, Argentina: communal roosts and conservation. *Oryx* 44:441–447. DOI: 10.1017/S0030605310000451
- Lambertucci SA, Carrete M, Donazar JA, Hiraldo F. 2012. Large-scale age-dependent skewed sex ratio in a sexually dimorphic avian scavenger. *PLoS ONE* 7:e46347. DOI: 10.1371/journal.pone.0046347
- Lambertucci SA, Donazar JA, Delgado Huertas A, et al. 2011. Widening the problem of lead poisoning to a South American top scavenger: lead concentrations in feathers of wild Andean Condors. *Biol Cons* 144:1464–1471.
- Lepeschkin E, Katz LN, Schaefer H, Shanes AM, Weidmann S. 1957. The U wave and afterpotentials in cardiac muscle: panel discussion. *Ann NY Acad Sci* 65:942–959.
- López Murcia MM, Bernal LJ, Montes AM, García Martínez JD, Ayala I. 2005. The normal electrocardiogram of the unanesthetized competition “Spanish Pouter” Pigeon (*Columba livia gutturosa*). *J Vet Med A* 52:347–349.
- Lumeij JT, Stokhof AA. 1985. Electrocardiogram of the racing pigeon (*Columba livia domestica*). *Res Vet Sci* 38:275–278.
- Lumeij JT, Ritchie BW. 1999. Cardiology. In: Ritchie BW, Harrison GJ, Harrison LR, editors. *Avian medicine: principles and application*. Florida, USA: HBB International, Delray Beach. p 695–722.
- Mandel JT, Bildstein KL, Bohrer G, Winkler DW. 2008. Movement ecology special feature: movement ecology of migration in turkey vultures. In: *Proceedings of the National Academy of Sciences, USA*, 19102–119107.
- Martinez LA, Jeffrey JS, Odom TW. 1997. Electrocardiographic diagnosis of cardiomyopathies in aves. *Poult Avian Biol Rev* 8:9–20.
- McKenzie BE, Will JA, Hardie A. 1971. The electrocardiogram of the turkey. *Avian Dis* 15:737–744.
- McKenzie BE, Will JA. 1972. Electrocardiographic changes following influenza infection in turkeys. *Avian Dis* 16:308–318.
- Miller MS. 1986. Electrocardiography. In: Harrison GJ, Harrison LR, editors. *Clinical avian medicine and surgery*. Philadelphia, Pennsylvania, USA: WB Saunders Company. p 286–292.
- Mirvis DM, Goldberger AL. 2007. Electrocardiography. In: *Intraventricular conduction delays*. In: Braunwald E, editor. *Braunwald's heart disease: a textbook of cardiovascular medicine*, 8th Ed. Philadelphia, USA: Saunders Elsevier. p 167.
- Mitchell BW, Brugh M. 1982. Comparison of electrocardiograms of chickens infected with viscerotropic velogenic Newcastle disease virus and virulent avian influenza virus. *Am J Vet Res* 43:2274–2278.
- Nap AM, Lumeij JT, Stokhof AA. 1992. Electrocardiogram of the African grey (*Psittacus erithacus*) and Amazon (*Amazona spp.*) parrot. *Avian Pathol* 21:45–53.
- Navas-Ancien A, Silbergeld E, Rothenberg SJ. 2007. Lead exposure and cardiovascular disease—a systematic review. *Environ Health Perspect* 115:472–482.
- Oglesbee BL, Hamlin R, Klingaman H, Cianciola J, Hartman S. 2001. Electrocardiographic reference values for Macaws (*Ara species*) and Cockatoos (*Cacatua species*). *J Avian Med Surg* 15:17–22.
- Pattee OH, Carpenter JW, Fritts SH, et al. 2006. Lead poisoning in captive Andean condors (*Vultur gryphus*). *J Wildl Dis* 42:772–779.
- Pérez Riera AR, Ferreira C, Ferreira C, et al. 2008. The enigmatic sixth wave of the electrocardiogram: the U wave. *Cardiol J* 15:408–421.
- Prinzinger R, Nagel B, Bahat O, et al. 2002. Energy metabolism and body temperature in the Griffon Vulture (*Gyps fulvus*) with comparative data on the Hooded Vulture (*Necrosyrtes monachus*) and the White-backed Vulture (*Gyps africanus*). *J Ornithol* 143:456–467.
- Rodríguez R, Prieto-montaña F, Montes AM, et al. 2004. The normal electrocardiogram of the unanesthetized peregrine falcon (*Falco peregrinus brookei*). *Avian Dis* 48:405–409.
- Schimpf R, Antzelevitch C, Haghi D, et al. 2008. Electromechanical coupling in patients with the short QT syndrome: further insights into the mechano-electrical hypothesis of the U wave. *Heart Rhythm* 5:241–245.
- Shepard ELC, Lambertucci SA, Vallmitjana D, Wilson RP. 2011. Energy beyond food: foraging theory informs time spent in thermals by a large soaring bird. *PLoS ONE* 6:e27375. DOI: 10.1371/journal.pone.0027375
- Smith SA, Paselk RA. 1986. Olfactory sensitivity of the turkey vulture (*Cathartes aura*) to three carrion associated odorants. *Auk* 103:586–592.
- Sturkie PD. 1949. The electrocardiogram of the chicken. *Am J Vet Res* 10:168–175.
- Sturkie PD. 1952. Effects of acute thiamine deficiency on the electrocardiogram of the chick. *Poult Sci* 31:648–650.
- Szabuniewicz M, McCrady JD. 1974. The electrocardiogram of the Japanese Quail (*Coturnix coturnix japonica*) and Bobwhite (*Colinus virginianus*) Quail. *J Vet Med A* 21:198–207.
- Talavera J, Guzmán MJ, Fernández del palacio MJ, Albert AP, Bayón A. 2008. The normal electrocardiogram of four species of conscious raptors. *Res Vet Sci* 84:119–125.
- Tilley LP. 1992. *Essentials of canine and feline electrocardiography*, 3rd Ed. St. Louis, Philadelphia Lea & Febiger, USA.