

Retinoic Acid as a Novel Medical Therapy for Cushing's Disease in Dogs

Victor Castillo, Damiana Giacomini, Marcelo Páez-Pereda, Johanna Stalla, Marta Labeur, Marily Theodoropoulou, Florian Holsboer, Ashley B. Grossman, Günter K. Stalla, and Eduardo Arzt

Unidad de Endocrinología (V.C.), Hospital Escuela, Facultad de Ciencias Veterinarias, and Laboratorio de Fisiología y Biología Molecular (D.G., E.A.), Departamento de Fisiología, Biología Molecular y Celular, Facultad Ciencias Exactas y Naturales, Universidad de Buenos Aires, 1428 Buenos Aires, Argentina; Max-Planck-Institute of Psychiatry (M.P.-P., J.S., M.L., M.T., F.H., G.K.S.) and Affectis Pharmaceuticals (M.P.-P.), 80804 Munich, Germany; Department of Endocrinology (A.B.G.), Barts and the London School of Medicine and Dentistry, Queen Mary University of London, London EC1A 7BE, United Kingdom; and Instituto de Fisiología, Biología Molecular y Neurociencias-Argentine National Research Council (E.A.), Consejo Nacional de Investigaciones Científicas y Técnicas, 1428 Buenos Aires, Argentina

Cushing's disease is almost always caused by an ACTH-secreting pituitary tumor, but effective medical therapy is currently limited. Because retinoic acid has been shown to be potentially useful in decreasing corticotroph secretion and proliferation in rodent models, we have studied its action in dogs with Cushing's disease. A randomized treatment with retinoic acid ($n = 22$) vs. ketoconazole ($n = 20$) in dogs with Cushing's disease was assigned for a period of 180 d. Clinical signs, plasma ACTH and α -MSH, the cortisol/creatinine urine ratio, and pituitary magnetic resonance imaging were assessed and compared at different time points. We recorded a significant reduction in plasma ACTH and α -MSH, and also in the cortisol/creatinine urine ratio, of the dogs treated with retinoic acid.

Pituitary adenoma size was also significantly reduced at the end of retinoic acid treatment. Survival time and all the clinical signs evaluated showed an improvement in the retinoic-acid-treated dogs. No adverse events or signs of hepatotoxicity were observed, suggesting that the drug is not only effective but also safe. Retinoic acid treatment controls ACTH and cortisol hyperactivity and tumor size in dogs with ACTH-secreting tumors, leading to resolution of the clinical phenotype. This study highlights the possibility of using retinoic acid as a novel therapy in the treatment of ACTH-secreting tumors in humans with Cushing's disease. (*Endocrinology* 147: 4438–4444, 2006)

PITUITARY TUMORS COMPRISE some 10% of intracranial neoplasms, and many of these are secretory. Although the primary therapy for nonsecretory adenomas is surgical, many of the secreting tumors may now be managed, as primary or secondary treatment, with medical therapy. Thus, the majority of prolactin-secreting tumors, prolactinomas, may be treated with dopamine agonist drugs such as cabergoline (1), whereas GH-secreting tumors will frequently respond to somatostatin analog therapy, both in terms of hormone secretion as well as tumor shrinkage (2, 3). However, for ACTH-secreting pituitary tumors causing pituitary-dependent Cushing's syndrome, Cushing's disease, only a minority respond to treatment with dopamine agonists or somatostatin analogs (4–6), and the primary mode of therapy remains transsphenoidal surgery. Such corticotroph cell adenomas, or corticotrophinomas, account for approximately 8% of all clinically recognized pituitary adenomas, possibly more when considering silent corticotroph

adenomas (7, 8). The glucocorticoid hypersecretion secondary to Cushing's disease causes significant morbidity, but unfortunately transsphenoidal surgery is associated with only a 60–80% cure rate for microadenomas, even in the most experienced hands, as well as a significant rate of recurrence; the cure rate is even less for macroadenomas. In addition, bilateral adrenalectomy can give rise to progression of the pituitary tumor, Nelson's syndrome, in a large minority of patients (9–12).

Some pharmacological agents have been proposed for the medical treatment of Cushing's disease (5, 6, 13, 14). Octreotide, a somatostatin analog, and dopaminergic and serotonergic drugs have been used to control ACTH secretion and tumor growth (5), but they have shown no consistently effective results in a large number of patients for extended periods. Several adrenal target drugs, such as ketoconazole, have also been used (5, 13, 14), but although they control the excessive glucocorticoid secretion in some patients, they do not inhibit corticotrophinoma growth and its consequent effects and are not a real alternative to the established procedures.

Ligands for the nuclear receptor, peroxisome proliferator-activated receptor- γ (PPAR- γ), induce cell-cycle arrest and apoptosis in corticotrophinoma cells, induced tumor growth arrest *in vivo* in a nude mouse model, and inhibited ACTH and corticosterone secretion from tumor cells (15) but seem not to be effective in humans according to small-scale clinical trials (16). Retinoic acid is an agent that has been shown to

First Published Online June 1, 2006

Abbreviations: ALP, Alkaline phosphatase; GOT, glutamyl oxaloacetic transaminase; GTP, glutamate-pyruvate transaminase; Ktz, ketoconazole-treated; MRI, magnetic resonance imaging; POMC, proopiomelanocortin; PPAR- γ , peroxisome proliferator-activated receptor- γ ; RC/C, cortisol/creatinine; Rx, retinoic-acid-treated; RXR, retinoic X receptor.

Endocrinology is published monthly by The Endocrine Society (<http://www.endo-society.org>), the foremost professional society serving the endocrine community.

inhibit proliferation, invasion, and tumor growth *in vivo* and induces differentiation and apoptosis in different cell types (17–19). Some of these effects are mediated by a reduction in binding of the transcription factors AP-1 and Nur77 to their cognate DNA sites (20, 21); these factors are also essential in the control of the proopiomelanocortin (POMC) gene (22–24), which gives rise to the precursor to ACTH and α -MSH. Very recently, we have shown that retinoic acid inhibits ACTH secretion both *in vitro* and *in vivo* through an action on POMC gene transcription and also inhibits corticotrophinoma development and proliferation (25).

Recently, the genome sequence of the domestic dog has been published, these data providing considerable information as to the evolution of this species. However, in addition, because of the similarity of canine to many human diseases, it has been suggested that the dog may help to bridge the gap between preclinical drug studies and the effects of the same drug in humans (26). Cushing's disease is a common disorder in dogs and one in which the histopathology is broadly similar to that in the human and for which the treatment is also primarily surgical where available (27). We therefore speculated that retinoic acid may be useful therapeutically in the treatment of canine Cushing's disease and have assessed its use in this species as a specific treatment modality and as an initial model system for the human (26). Our results suggest that retinoic acid may indeed be a potent medical treatment for Cushing's disease, and human trials are now warranted.

Materials and Methods

Population under study

We selected 42 dogs with Cushing's disease (15 males) seen sequentially according to the following criteria: the presence of at least four clinical signs characteristic of the disease, urinary values for the cortisol μ mol/liter:creatinine μ mol/liter ratio greater than 70 nmol/liter, a detectable plasma ACTH, and evidence of a pituitary adenoma on magnetic resonance imaging (MRI). These criteria are considered pathognomonic of an anterior lobe corticotrophinoma (27). The animals were studied at the Endocrinology Unit of the School Hospital of the Faculty of Veterinary Sciences, University of Buenos Aires, Argentina. The average age of the animals at the time of diagnosis was 9 yr (95% confidence limits, 8.2–9.9 yr; range, 3–14 yr) without significant difference between males and females. At the time of diagnosis, no animal presented any concurrent disease other than that associated with Cushing's disease, which included elevations in serum transaminases glutamate-pyruvate transaminase (GTP) and glutamyl oxaloacetic transaminase (GOT) and alkaline phosphatase (ALP) previously described in dogs with Cushing's disease (27).

All dogs seen and following the above stated criteria were consecutively included in the study and were alternatively randomly distributed into two groups: 1) a retinoic-acid-treated (Rx) group of 22 dogs (seven males and 15 females, of which 12 were not castrated and were anestrus for at least 18 months and three were castrated) were treated with 2 mg/kg body weight/d of 9-*cis* retinoic acid (Roche, Basel, Switzerland); and 2) a ketoconazole-treated (Ktz) group (control) of 20 dogs (eight males and 12 females, none of which were castrated and all were anestrus for >18 months) were treated with 20 mg/kg body weight/d ketoconazole (Jenssen Laboratories, Buenos Aires, Argentina). Ketoconazole is a drug that interferes with steroid biosynthesis and is a standard therapy for canine Cushing's disease (28); it was used for comparison because of ethical and legal reasons that would not allow us to leave animals without an already proven treatment. The dogs comprised a variety of breeds, but these were randomly allocated between the two groups; 9-*cis* retinoic acid was chosen because it binds both retinoic acid receptor and retinoid X receptor (RXR) (18, 29). The dose of ketoconazole

was based on current therapeutic custom, whereas the retinoic acid dosage was based on current clinical therapy in the human and the results of pilot studies.

Study protocol

Drugs were administered for 180 d. During this period, hepatic enzyme activity (ALP, GTP, and GOT) was measured by a kinetic automated method (Metrolab, Merck Autoanalyzer; Merck, Darmstadt, Germany) every 30 d; an increase of more than three times the ALP and GTP or of two times the GOT values found at the time of diagnosis was considered to indicate hepatocyte necrosis and as a reason for suspension of treatment, but in no animal was this threshold breached. None of the animals treated with any of the drugs showed any clinical signs of hepatic dysfunction during or after the treatment.

Clinical signs

The following clinical signs, considered critical in dog Cushing's disease (27), were monitored by a single observer. 1) Fluid ingestion and micturition were evaluated by means of measurement of daily intake of water (100 ml/kg·d maximum); polydipsia and polyuria were present in 88% of the cases before treatment. 2) Solid ingestion, assessed by the frequency of food intake (more than three daily meals), was monitored. Hyperphagia was initially present in 81% of the cases. 3) Estrous cyclicity, in terms of a return of the cycle in those females who were not castrated, was recorded. 4) Dermatological signs such as the elasticity and thickness of the skin and the presence of striae were noted as well as partial or total loss of body hair and its oiliness and brightness. Such dermatological signs were present in 76% of the dogs diagnosed with Cushing's disease. 5) Abdominal swelling, either normal or a ball form, was recorded. The ball form was present in 93% of dogs before treatment. 6) An increase in weight was noted by 95% of dog owners before treatment. Given the variability in dog size, weight changes after treatment are expressed as percent change with respect to the weight at the beginning.

Biochemical and endocrine studies

For the cortisol/creatinine (RC/C) urine ratio, the methodology used was previously described by Rijnberk and colleagues (30) and modified in the Faculty of Veterinary Sciences, University of Buenos Aires. Representative 24-h urine samples were collected (an aliquot of 2 ml for each) as follows: the second voided urine in the morning, all urines during the rest of the day and the last one at night, and the first urine of the following day. Urinary cortisol was measured by a commercial RIA using solid-phase technology (DPC Corp., San Diego, CA) and creatinine by an automated kinetic method according to the manufacturer's instructions (Metrolab Autoanalyzer; Merck). The inter- and intraassay coefficients of variation were 8 and 5%, respectively, and the sensitivity was 1 nmol/liter. Evaluation times were at time 0 (at diagnosis), at 120 d (in treatment), and at 180 d (end of treatment).

Plasma ACTH and α -MSH were assayed on samples taken between 1300 and 1400 h because the dog shows circadian rhythmicity with a marked increase in plasma ACTH at this time of the day (31). ACTH (Nichols Advantage ACTH Assay; Nichols Institute Diagnostics, Bad Vilbel, Germany) and α -MSH (Euro-Diagnostica AB, Malmö, Sweden) were measured by RIA as previously described (32). Both assays are established procedures in veterinary medicine (33). Both hormones were evaluated monthly from time 0 (diagnosis) to 180 d/6 months (end of treatment). The intraassay coefficients of variation for the ACTH immunoassay were 3 and 3.2% for mean values of 35 or 366 pg/ml, respectively, with interassay coefficients of variation of 7.8 and 6.8% for mean values of 36 or 358 pg/ml, respectively. The intraassay coefficients of variation for α -MSH were 11.8, 4.7, and 2.9% for mean values of 6.2, 33.6, and 77.7 pmol/liter, respectively, with interassay values of 13.0, 8.4, and 4.0% for α -MSH at 16.5, 37.8, and 79.6 pmol/liter, respectively. The sensitivity was 3 pmol/liter.

Diagnostic imaging

MRI of the sellar region was performed using sagittal, coronal, and axial cuts of 2 mm each with gadolinium enhancement. The tumor size

was calculated on the basis of the coronal and sagittal cuts passing through the mean line of both planes; the height of the adenoma was measured from the base. The MRI study was made at time 0 (diagnosis) and at 180 d/6 months (end of treatment) using the same equipment and operator, who was unaware of the specific treatment.

Statistical analysis

All results are expressed as medians and ranges. The comparison between intra- and intergroup ACTH, α -MSH, and RC/C averages were made by means of the nonparametric ANOVA followed by Dunn's test for multiple comparisons. The intragroup tumor size and pre- and posttreatment results were analyzed with Wilcoxon's test. The clinical data were evaluated by means of the table of contingency (χ^2 with Yate's correction) followed by Fisher's exact test and determination of the odds ratio (OR) between both groups after treatment. Survival curves were constructed and evaluated by means of the log-rank χ^2 test.

Ethical approval

The Ethics Committee of the Faculty of Veterinary Sciences and the Secretary of Sciences of the Universidad de Buenos Aires (UBACYT-V045 project) approved the present study, according to the laws on experimentation in animals in Argentina and World Health Organization recommendations. The signed consent of the dog owners was obtained for participation in the present project.

Results

Levels of plasma ACTH and α -MSH and urinary cortisol in dogs with Cushing's disease treated with retinoic acid compared with ketoconazole

Before treatment, dogs in both groups had similar levels of ACTH, α -MSH, and urinary cortisol. In the Ktz group, there were no significant changes in ACTH or α -MSH at any of the times studied. However, as shown in Fig. 1A, in the Rx group, a significant decrease was observed in plasma ACTH at 90 d of treatment in comparison with time 0 ($P < 0.01$), and this fall was maintained until the end of the study ($P < 0.01$ for 150 *vs.* 0 d; $P < 0.001$ for 120 and 180 *vs.* 0 d). The differences between the treatment groups were statistically significant at 120 d ($P < 0.05$), 150 d ($P < 0.01$), and 180 d ($P < 0.001$). As shown in Fig. 1B, plasma α -MSH also showed a similar reduction with retinoic acid treatment. In the Rx group, a significant reduction was observed at 90 *vs.* 0 d ($P < 0.05$), remaining significantly suppressed until the end of the study ($P < 0.001$ for 120, 150, and 180 *vs.* 0 d). Significant differences between the groups were observed at 120 d ($P < 0.05$).

The RC/C ratio (Fig. 1C) decreased significantly in both groups from 120 d; this reduction was more evident in the Rx group and was significantly different between the groups at 180 d ($P < 0.01$). The fall in urinary cortisol in the Rx group paralleled the reduction in plasma ACTH.

Tumor size reduction after retinoic acid treatment

In the Rx group, pituitary adenoma size, as assessed by MRI, was significantly reduced at the end of the treatment compared with the baseline ($P < 0.008$; Fig 2). In only a single case was there no obvious decrease in tumor size. In the Ktz group, no significant variation in the size of the pituitary adenoma was observed (data not shown), correlating with the fact that the pituitary hormones also remained stable.

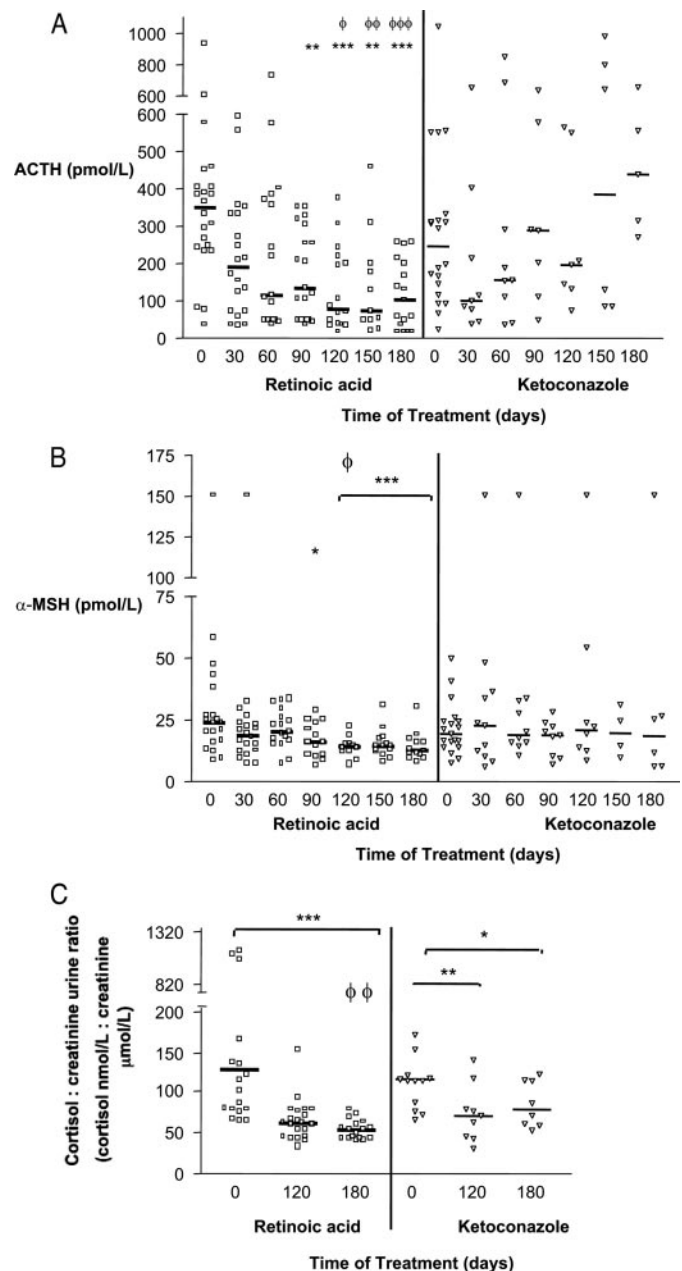


FIG. 1. Changes in ACTH, α -MSH, and urinary cortisol in dogs with Cushing's disease treated with 2 mg/kg body weight/d of retinoic acid (isotretinoin 9-*cis*) (Rx) *vs.* a control group treated with 20 mg/kg body weight/d of ketoconazole. A, Intra-Rx group *vs.* time zero: **, $P < 0.01$ for 90 and 150 d; ***, $P < 0.001$ for 120 and 180 d. There were not significant differences from baseline in the Ktz group. Ktz *vs.* Rx group: ϕ , $P < 0.05$ for 120 d Rx *vs.* 120 d Ktz; $\phi\phi$, $P < 0.01$ for 150 d Rx *vs.* 150 d Ktz; $\phi\phi\phi$, $P < 0.001$ for 180 d Rx *vs.* 180 d Ktz. B, Intra-Rx group *vs.* time zero: *, $P < 0.05$ for 90 d; ***, $P < 0.001$ for 120, 150, and 180 d. There were not significant differences in the Ktz group. Ktz *vs.* Rx group: ϕ , $P < 0.05$ for 120 d Rx *vs.* 120 d Ktz. C, Intra-Rx group *vs.* time zero: ***, $P < 0.001$ for 180 d. Intra-Ktz group *vs.* time zero: **, $P < 0.01$ for 120 d; *, $P < 0.05$ for 180 d. Ktz *vs.* Rx group: $\phi\phi$, $P < 0.01$ for 180 d Rx *vs.* 180 d Ktz. Values are expressed as median and range. ANOVA-Dunn's test (intra- and intergroup). Open squares (Rx) and triangles (Ktz) represent individual dogs and their variation during treatment.

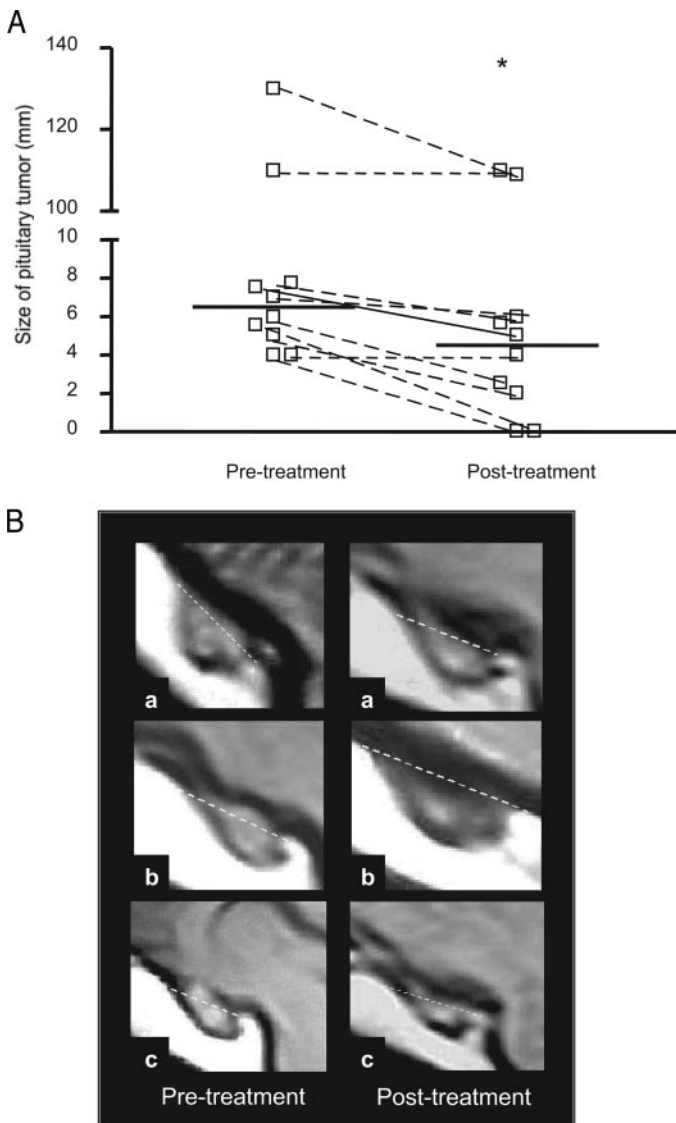


FIG. 2. The size of the pituitary tumor in dogs with Cushing's disease before and after treatment with 2 mg/kg body weight/d of retinoic acid (isotretinoin 9-*cis*). A, The *open squares* represent each individual dog pituitary tumor and its variation after 6 months of treatment. *, $P < 0.008$ pretreatment *vs.* posttreatment (Wilcoxon's test). Values are expressed as median and range. B, MRI sagittal views of three representative dogs (a–c) where the changes in tumor size are shown. The *broken line* shows the top of the sella turcica with evidence of tumor size reduction.

Survival curve and clinical signs

Of the total number of dogs that were initiated into the study (Table 1), five dogs ceased treatment in the Rx group; two died secondary to complications of Cushing's disease (tumor apoplexy) and one of cardiac insufficiency, whereas two were removed from the study (one because of footpad hyperkeratosis with pain on weight bearing, the other because of the owner's decision). By contrast, 11 dogs in the Ktz group died, 10 because of adverse effects related to Cushing's disease and one case of tumor apoplexy, and one left because of owner's choice. The time of survival after initiation of treatment was significantly longer in the Rx group compared

with the Ktz group, of which more than 50% of the dogs died before 180 d (Fig. 3).

Of the clinical signs monitored, weight was the only parameter studied that did not show significant differences between the groups. During the study period, there was a decline in mean body weight in both groups ($-8.98 \pm 6.1\%$ in the Rx group *vs.* $-9.2 \pm 8.5\%$ in the Ktz group; $P > 0.05$, not significant). Retinoic acid induced an improvement in all the clinical signs evaluated (return of estrus, food intake, skin appearance, and hair loss; Table 1). Resumption of normal gonadal activity, observed in 10 of 12 females in the Rx group, occurred between 3 and 5 months after initiation of the therapy, correlating with the observed reduction in the ACTH and urinary cortisol concentrations. At the present moment, some 6–12 months after completion of the trial and cessation of treatment, none of the dogs treated with retinoic acid has shown evidence of recurrence of Cushing's disease.

Discussion

Ketoconazole is an established treatment for Cushing's disease, both in the human and in dogs, which operates by interfering with steroid biosynthetic pathways. In this study we show that retinoic acid is at least as effective as ketoconazole, if not more so, but the fall in cortisol excretion is accompanied by a reduction in circulating ACTH and α -MSH and a reduction in size of the pituitary tumor. This supports the concept that retinoic acid may improve the clinical and biochemical signs of Cushing's disease by a direct action on the tumorous corticotroph, as suggested by earlier studies in rodents (25). In dogs, two convertase enzymes are involved in processing the POMC gene products; one of these systems is active in the cells of the anterior pituitary that secrete ACTH, whereas the other is located in the intermediate-lobe cells that predominantly secrete α -MSH (34). In the present study, a reduction in both hormones was seen, suggesting that retinoic acid acts on the pituitary adenoma arising not only from the anterior lobe but also from the normal intermediate lobe. However, it cannot be excluded that the α -MSH originated from the tumor *per se*. This modulation of the activity of Cushing's disease was associated with increased survival, with only a single animal dying from cardiac failure, a complication possibly related to hypercortisolemia. By contrast, in the Ktz group, more than 50% of the animals died before completing the treatment, usually from complications of the glucocorticoid excess, with survival similar to that previously documented for ketoconazole (28). We would attribute this to more effective control of the hypercortisolemia in the Rx group.

There was a remarkable improvement in clinical signs in the Rx group. Fluid intake fell, presumably as a consequence of an increase in renal blood flow and inhibition of the salt-retaining effects of cortisol (27), and there was a return of normal gonadal function with disease control (35). It would therefore appear that retinoic acid treatment, via a reduction in ACTH and cortisol levels, leads to normalization of the gonadal axis and the estrous cycle. Reversal of anestrus occurred at 90 and 150 d after the initiation of the therapy, coincident with a reduction in ACTH and RC/C. This may

TABLE 1. Changes in clinical signs observed in dogs with Cushing's disease treated with 2 mg/kg body weight/d of retinoic acid compared with 20 mg/kg weight/d ketoconazole

Clinical signs	Retinoic acid		Ketoconazole		OR
	Pretreatment	Posttreatment	Pretreatment	Posttreatment	
Survivor at end of treatment (death or abandon/alive) ^a		5/17		12/8	0.2
Water intake (abnormal/normal intake) ^b	20/2	0/17	17/3	5/3	0.018
Estrus state (anestrus/estrus) ^c	12/0	2/10	12/0	4/1	0.05
Polyphagia (with/without) ^d	18/4	2/15	16/4	4/4	0.133
Skin (abnormal/normal) ^e	16/6	5/12	16/4	6/2	0.14
Hair (abnormal/normal) ^f	13/9	3/14	14/6	4/4	0.21
Abdomen (prominent/normal) ^g	21/1	11/6	18/2	5/3	1.1
Weight (% reduction from pretherapy) ^h		-8.98 ± 6.1		-9.2 ± 8.5	

Pretreatment Rx group n = 22; posttreatment Rx group n = 17; pretreatment Ktz group n = 20; posttreatment Ktz group n = 8. All data are expressed as number of cases (with alteration in sign/improved or normal sign). Contingency table and Fisher's exact test were used for all statistical analyses. OR represents odds ratio for posttreatment Rx *vs.* Ktz group.

^a $P < 0.03$ post-Rx *vs.* post-Ktz. In the Rx group, two dogs died from illness, one of them at the end of treatment (both had macroadenomas), two dogs abandoned the study, and one dog died from a cardiac failure previously diagnosed. All deaths of dogs in the Ktz group were secondary to Cushing's disease.

^b $P < 0.001$ post-Rx *vs.* pre-Rx and post-Rx *vs.* post-Ktz.

^c $P < 0.03$ post- *vs.* pretreatment Rx. From 12 unneutered bitches in both groups, 10 of 12 in the Rx group and one of four in the Ktz group (seven bitches died during the treatment time) normalized its reproductive function. Sexual function returned 3–4 months from the beginning of therapy with retinoic acid and 5 months with ketoconazole in the single bitch.

^d $P < 0.0001$ post- *vs.* pretreatment Rx.

^e $P < 0.01$; ^f $P < 0.02$; post- *vs.* pretreatment Rx. The dermatological signs of Cushing's disease in dogs include changes in skin and hair resulting in several changes in structure (inelasticity, atrophy of the epidermis and dermis layers, loss of hair, and seborrhea).

^g $P < 0.03$ post- *vs.* pretreatment Rx. Prominent abdomen is caused by a large amount of visceral fat and enlargement of the liver. Reduction of the abdominal fat results in decreased size.

^h Weight is expressed as average ± SD. A reduction was observed in both Rx and Ktz groups with respect to the initial values, with no significant difference between groups.

be contrasted with the results observed in the Ktz group, in which estrous cyclicity was restored in only a single female. In humans, too, Cushing's syndrome is associated with go-

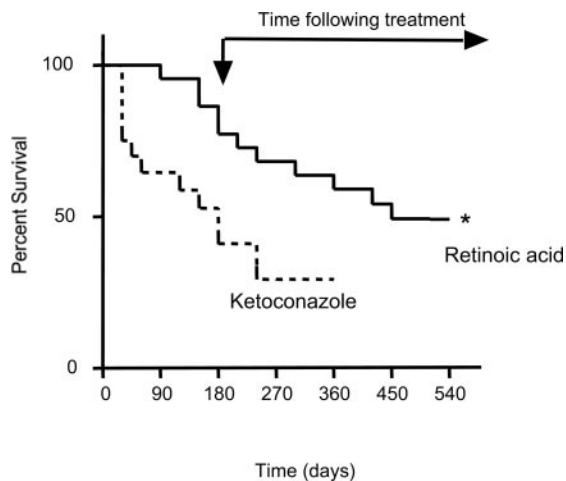


FIG. 3. Survival curves in dogs with Cushing's disease treated with 2 mg/kg body weight/d of retinoic acid (isotretinoin 9-*cis*) *vs.* 20 mg/kg weight/d of ketoconazole. The time of treatment was 180 d; after that, the dogs were assessed in the absence of drug therapy. *, $P < 0.008$ for retinoic acid *vs.* ketoconazole (log-rank test χ^2). The normal life expectancy of the dog is approximately 13–15 yr. At 540 d, 1 yr after completion of the treatment, four dogs in the Rx group had died because of age [age > 12 yr (12–15 yr)], two dogs had left the study because the owner had withdrawn permission, and one had died of pulmonary fibrosis (not related to the disease) caused by a pneumonia acquired after treatment. In summary, over 1 yr after completion of retinoic acid treatment, a total of seven dogs previously receiving retinoic acid treatment either died for reasons unrelated to the disease or left the study; none died from complications of Cushing's disease.

nadal dysfunction, which improves with effective therapy (36).

By contrast, a similar weight reduction was observed in both groups, presumably secondary to the fall in cortisol with both drugs. An interaction between retinoic acid (through the RXR) with PPAR- γ has also recently been described (37). This interaction regulates the process of gluconeogenesis in adipose tissue by the expression of the cytosolic form of phosphoenolpyruvate carboxykinase (38). Thus, the Rx group would have an additional effect because of the interaction of retinoic acid and PPAR- γ in controlling intra-adipocyte gluconeogenesis.

No adverse events with retinoic acid were recorded, except for one case of footpad hyperkeratosis, and there was no evidence of hepatotoxicity during or after the study in terms of hepatic enzyme abnormalities. Based on these data, the dose of retinoic acid used (2 mg/kg body weight/d) was not only effective but also appeared to be safe.

The mode of action of retinoic acid involves an interaction with retinoic acid receptor and RXR (18, 29). Earlier work has demonstrated that retinoic acid blocks the activation of POMC transcription by the orphan receptors Nur77 and Nurr1, that this process is particularly potent in tumorous as opposed to normal tissue, and that it is associated with a decrease in adenomatous proliferation and increased apoptosis (25). The dose requirements in rodents is within an order of magnitude of that used in the current studies and not far removed from therapeutic doses of this drug used in the human for other conditions (17, 25). The current findings suggest that studies in rodents can be extrapolated to the dog and are likely to be therapeutically relevant to the human.

In summary, we describe the effect of retinoic acid in

Cushing's disease in dogs, where a well tolerated dose regimen was highly effective in reducing the overactivity of the pituitary-adrenal axis and was associated with shrinkage of the corticotrophinoma. Retinoic acid produced an improvement in all clinical signs monitored and increased survival compared with ketoconazole. This study highlights the possibility of using retinoic acid as a medical therapy for ACTH-secreting tumors in human patients, for whom there is no generally effective pharmacological therapy. Long-term clinical trials in patients will be needed to determine whether retinoic acid has the same observed effects that we have shown in this animal model.

Acknowledgments

We thank Dr. Ulf-W. Wiegand, from F. Hoffmann-La Roche Ltd., for providing the retinoic acid (Roaccutan), Dr. Horacio Farfallini who facilitated performance of MRI in the dogs, and the Hospital Escuela de la Facultad de Ciencias Veterinarias-UBA establishment for their collaboration in referring cases.

Received March 30, 2006. Accepted May 23, 2006.

Address all correspondence and requests for reprints to: Prof. A. B. Grossman, Department of Endocrinology, St. Bartholomew's Hospital, London EC1A 7BE, United Kingdom. E-mail: A.B.Grossman@qmul.ac.uk; or Prof. E. Arzt, Laboratorio Fisiología y Biología Molecular, Departamento de Fisiología, Biología Molecular y Celular, FCEN, Universidad de Buenos Aires, Ciudad Universitaria, Pabellon II, 1428 Buenos Aires, Argentina. E-mail: earzt@fbmc.fcen.uba.ar.

This work was supported by grants from the University of Buenos Aires (UBACYT project V045), the Argentine National Research Council (CONICET) and Agencia Nacional de Promoción Científica y Tecnológica-Argentina.

Disclosure statement: V.C., D.G., M.P.-P., J.S., M.L., M.T., F.H., A.B.G., G.K.S., and E.A. have nothing to declare.

References

1. Bevan JS, Webster J, Burke CW, Scanlon MF 1992 Dopamine agonists and pituitary tumor shrinkage. *Endocr Rev* 13:220–240
2. Bevan JS 2005 The antitumoral effects of somatostatin analog therapy in acromegaly. *J Clin Endocrinol Metab* 90:1856–1863
3. Melmed S, Sternberg R, Cook D, Klibanski A, Chanson P, Bonert V, Vance ML, Rhew D, Kleinberg D, Barkan A 2005 A critical analysis of pituitary tumor shrinkage during primary medical therapy in acromegaly. *J Clin Endocrinol Metab* 90:4405–4410
4. Pivonello R, Ferone D, de Herder WW, de Krijger RR, Waaijers M, Mooij DM, van Koetsveld PM, Barrea A, De Caro ML, Lombardi G, Colao A, Lamberts SW, Hofland LJ 2004 Dopamine receptor expression and function in human normal adrenal gland and adrenal tumors. *J Clin Endocrinol Metab* 89:4493–4502
5. Boscaro M, Barzon L, Fallo F, Sonino N 2001 Cushing's syndrome. *Lancet* 357:783–791
6. De Herder WW, Lamberts SW 1999 Octapeptide somatostatin-analogue therapy of Cushing's syndrome. *Postgrad Med J* 75:65–66
7. Melmed S 2003 Mechanisms for pituitary tumorigenesis: the plastic pituitary. *J Clin Invest* 112:1603–1618
8. Dahia PL, Grossman AB 1999 The molecular pathogenesis of corticotroph tumors. *Endocr Rev* 20:136–155
9. Colao A, Di Sarno A, Marzullo P, Di Somma C, Cerbone G, Landi ML, Faggiano A, Merola B, Lombardi G 2000 New medical approaches in pituitary adenomas. *Horm Res* 53(Suppl 3):76–87
10. Newell-Price J, Bertagna X, Grossman AB, Nieman LK 2006 Cushing's syndrome. *Lancet* 367:1605–1617
11. Newell-Price J, Trainer P, Besser M, Grossman A 1998 The diagnosis and differential diagnosis of Cushing's syndrome and pseudo-Cushing's states. *Endocr Rev* 19:647–672
12. Arnaldi G, Angeli A, Atkinson AB, Bertagna X, Cavagnini F, Chrousos GP, Fava G, Findling JW, Gaillard RC, Grossman AB, Kola B, Lacroix A, Mancini T, Mantero F, Newell-Price J, Nieman LK, Sonino N, Vance ML, Giustina A, Boscaro M 2003 Diagnosis and complications of Cushing's syndrome: a consensus statement. *J Clin Endocrinol Metab* 88:5593–5602
13. Nieman LK 2002 Medical therapy of Cushing's disease. *Pituitary* 5:77–82
14. Morris D, Grossman A 2002 The medical management of Cushing's syndrome. *Ann NY Acad Sci* 970:119–133
15. Heaney AP, Fernando M, Yong WH, Melmed S 2002 Functional PPAR- γ receptor is a novel therapeutic target for ACTH-secreting pituitary adenomas. *Nat Med* 8:1281–1287
16. Ambrosi B, Dall'Asta C, Cannavo S, Libe R, Vigo T, Epaminonda P, Chiodini I, Ferrero S, Trimarchi F, Arosio M, Beck-Peccoz P 2004 Effects of chronic administration of PPAR- γ ligand rosiglitazone in Cushing's disease. *Eur J Endocrinol* 151:173–178
17. Kurie JM 1999 The biologic basis for the use of retinoids in cancer prevention and treatment. *Curr Opin Oncol* 11:497–502
18. Merino R, Hurle JM 2003 The molecular basis of retinoid action in tumors. *Trends Mol Med* 9:509–511
19. Lotan R 1996 Retinoids in cancer chemoprevention. *FASEB J* 10:1031–1039
20. Kang HJ, Song MR, Lee SK, Shin EC, Choi YH, Kim SJ, Lee JW, Lee MO 2000 Retinoic acid and its receptors repress the expression and transactivation functions of Nur77: a possible mechanism for the inhibition of apoptosis by retinoic acid. *Exp Cell Res* 256:545–554
21. Fanjul A, Dawson MI, Hobbs PD, Jong L, Cameron JF, Harlev E, Graupner G, Lu XP, Pfahl M 1994 A new class of retinoids with selective inhibition of AP-1 inhibits proliferation. *Nature* 372:107–111
22. Kovalovsky D, Refojo D, Liberman AC, Hochbaum D, Pereda MP, Coso OA, Stalla GK, Holsboer F, Arzt E 2002 Activation and induction of NUR77/NURR1 in corticotrophs by CRH/cAMP: involvement of calcium, protein kinase A, and MAPK pathways. *Mol Endocrinol* 16:1638–1651
23. Maira M, Martens C, Philips A, Drouin J 1999 Heterodimerization between members of the Nur subfamily of orphan nuclear receptors as a novel mechanism for gene activation. *Mol Cell Biol* 19:7549–7557
24. Philips A, Lesage S, Gingras R, Maira MH, Gauthier Y, Hugo P, Drouin J 1997 Novel dimeric Nur77 signaling mechanism in endocrine and lymphoid cells. *Mol Cell Biol* 17:5946–5951
25. Paez-Pereda M, Kovalovsky D, Hopfner U, Theodoropoulou M, Pagotto U, Uhl E, Lusa M, Stalla J, Grubler Y, Missale C, Arzt E, Stalla GK 2001 Retinoic acid prevents experimental Cushing syndrome. *J Clin Invest* 108:1123–1131
26. Lindblad-Toh K, Wade CM, Mikkelsen TS, Karlsson EK, Jaffe DB, Kamal M, Clamp M, Chang JL, Kulbokas EJ, Zody MC, Mauceli E, Xie X, Breen M, Wayne RK, Ostrander EA, Ponting CP, Galibert F, Smith DR, DeJong PJ, Kirkness E, Alvarez P, Biagi T, Brockman W, Butler J, Chin CW, Cook A, Cuff J, Daly MJ, Decaprio D, Gnerre S, Grabherr M, Kellis M, Kleber M, Bardeleben C, Goodstadt L, Heger A, Hitte C, Kim L, Koepfli KP, Parker HG, Pollinger JP, Searle SM, Sutter NB, Thomas R, Webber C, Baldwin J, Abebe A, Aboueleil A, Aftuck L, Ait-Zahra M, Aldredge T, Allen N, An P, Anderson S, Antoine C, Arachchi H, Aslam A, Ayotte L, Bachantsang P, Barry A, Bayul T, Benamara M, Berlin A, Bessette D, Blitshteyn B, Bloom T, Blye J, Boguslavskiy L, Bonnet C, Boukhgalter B, Brown A, Cahill P, Calixte N, Camarata J, Cheshatsang Y, Chu J, Citroen M, Collymore A, Cooke P, Dawoe T, Daza R, Decktor K, Degray S, Dhargay N, Dooley K, Dorje P, Dorjee K, Dorris I, Duffey N, Dupes A, Egbiremolen O, Elong R, Falk J, Farina A, Faro S, Ferguson D, Ferreira P, Fisher S, Fitzgerald M, Foley K, Foley C, Franke A, Friedrich D, Gage D, Garber M, Gearin G, Giannoukos G, Goode T, Goyette A, Graham J, Grandbois E, Gyaltsen K, Hafez N, Hagopian D, Hagos B, Hall J, Healy C, Hegarty R, Honan T, Horn A, Houde N, Hughes L, Hunnicutt L, Husby M, Jester B, Jones C, Kamat A, Kanga B, Kells C, Khazanovich D, Kieu AC, Kisner P, Kumar M, Lance K, Landers T, Lara M, Lee W, Leger JP, Lennon N, Leuper L, Levine S, Liu J, Liu X, Lokysang Y, Lokysang T, Lui A, Macdonald J, Major J, Marabella R, Maru K, Matthews C, McDonough S, Mehta T, Meldrim J, Melnikov A, Meneus L, Mihalev A, Mihova T, Miller K, Mittelman R, Mengla V, Mulrain L, Munson G, Navidi A, Naylor J, Nguyen T, Nguyen N, Nguyen C, Nicol R, Norbu N, Norbu C, Novod N, Nyima T, Olandt P, O'Neill B, O'Neill K, Osman S, Oyono L, Patti C, Perrin D, Phunkhang P, Pierre F, Priest M, Rachupka A, Raghuraman S, Rameau R, Ray V, Raymond C, Rege F, Rise C, Rogers J, Rogov P, Sahalie J, Settippalli S, Sharpe T, Shea T, Sheehan M, Sherpa N, Shi J, Shih D, Sloan J, Smith C, Sparrow T, Stalker J, Stange-Thomann N, Stavropoulos S, Stone C, Stone S, Sykes S, Tchuinga P, Tenzing P, Tesfaye S, Thoultsang D, Thoultsang Y, Topham K, Topping I, Tsamila T, Vassiliev H, Venkataraman V, Vo A, Wangchuk T, Wangdi T, Weiland M, Wilkinson J, Wilson A, Yadav S, Yang S, Yang X, Young G, Yu Q, Zainoun J, Zembek L, Zimmer A, Lander ES 2005 Genome sequence, comparative analysis and haplotype structure of the domestic dog. *Nature* 438:803–819
27. Ling GV, Stabenfeldt GH, Comer KM, Gribble DH, Schechter RD 1979 Canine hyperadrenocorticism: pretreatment clinical and laboratory evaluation of 117 cases. *J Am Vet Med Assoc* 174:1211–1215
28. Feldman EC, Bruyette DS, Nelson RW, Farver TB 1990 Plasma cortisol response to ketoconazole administration in dogs with hyperadrenocorticism. *J Am Vet Med Assoc* 197:71–78
29. Wei LN 2003 Retinoid receptors and their coregulators. *Annu Rev Pharmacol Toxicol* 43:47–72
30. Rijnberk A, van Wees A, Mol JA 1988 Assessment of two tests for the diagnosis of canine hyperadrenocorticism. *Vet Rec* 122:178–180
31. Orth DN, Peterson ME, Drucker WD 1988 Plasma immunoreactive proopiomelanocortin peptides and cortisol in normal dogs and dogs with Cushing's

- syndrome: diurnal rhythm and responses to various stimuli. *Endocrinology* 122:1250–1262
32. **Muller OA, Stalla GK, von Werder K** 1983 Corticotropin releasing factor: a new tool for the differential diagnosis of Cushing's syndrome. *J Clin Endocrinol Metab* 57:227–229
 33. **Bosje JT, Rijnberk A, Mol JA, Voorhout G, Kooistra HS** 2002 Plasma concentrations of ACTH precursors correlate with pituitary size and resistance to dexamethasone in dogs with pituitary-dependent hyperadrenocorticism. *Domest Anim Endocrinol* 22:201–210
 34. **Tanaka S** 2003 Comparative aspects of intracellular proteolytic processing of peptide hormone precursors: studies of proopiomelanocortin processing. *Zoolog Sci* 20:1183–1198
 35. **Ross EJ, Linch DC** 1982 Cushing's syndrome—killing disease: discriminatory value of signs and symptoms aiding early diagnosis. *Lancet* 2:646–649
 36. **Lado-Abeal J, Rodriguez-Arno J, Newell-Price JD, Perry LA, Grossman AB, Besser GM, Trainer PJ** 1998 Menstrual abnormalities in women with Cushing's disease are correlated with hypercortisolemia rather than raised circulating androgen levels. *J Clin Endocrinol Metab* 83:3083–3088
 37. **Gearing KL, Gottlicher M, Teboul M, Widmark E, Gustafsson JA** 1993 Interaction of the peroxisome-proliferator-activated receptor and retinoid X receptor. *Proc Natl Acad Sci USA* 90:1440–1444
 38. **Beale EG, Hammer RE, Antoine B, Forest C** 2004 Disregulated glyceroneogenesis: PCK1 as a candidate diabetes and obesity gene. *Trends Endocrinol Metab* 15:129–135

Endocrinology is published monthly by The Endocrine Society (<http://www.endo-society.org>), the foremost professional society serving the endocrine community.