Rev Clin Esp. 2014;xxx(xx):xxx.e1–xxx.e3

Revista Clínica Española

www.elsevier.es/rce

CLINICAL COMMUNICATION

Non-uremic calciphylaxis and *Chagas* disease

Calcifilaxis no urémica y enfermedad de Chagas

M.H. Vicco[a,*], F. Ferini[b], L. Rodeles[b], M. Baretta[b], I. Marcipar[a], O.A. Bottasso[c]

[a] *Laboratorio de Tecnología Inmunológica, Facultad de Bioquímica y Ciencias Biológicas, Universidad Nacional del Litoral, Ciudad Universitaria, Paraje ''El Pozo'', Santa Fe, CP: 3000, Argentina*
[b] *Servicio de Clínica Médica, Hospital J.B ''Iturraspe'', Bv. Pellegrini 3551, Santa Fe, CP: 3000, Argentina*
[c] *Instituto de Inmunología, Facultad de Medicina, Universidad Nacional de Rosario, Santa Fe 3102, Rosario, CP: 2002, Santa Fe, Argentina*

Received 3 February 2014; accepted 16 February 2014

Introduction

Calciphylaxis is defined as a syndrome characterized by calcification of small-vessels, and thrombosis leading to ischemia of overlying skin together with soft tissue necrosis. Clinically, patient presents violaceous skin discoloration in a *livedo reticularis* pattern, which subsequently become firm plaques progressing to deep painful necrotic ulcerations, secondary cutaneous infection and sepsis. Reports on mortality, usually from sepsis, have been as high as 80%.[1] Calciphylaxis has usually been reported in patients with end-stage renal disease or secondary to hyperparathyroidism. The pathogenesis of this condition is unclear. It is hypothesized that aberrant calcium–phosphorus metabolism would lead to calcification of small-vessels, most commonly observed in uremia-associated metabolic abnormalities. The increase of calcium–phosphorus product results in vascular calcification, and subsequent thrombosis of luminal narrowed vasculature promoting end-organ hypoperfusion.[2] However, calciphylaxis has also been described in patients with normal renal and parathyroid function – non uremic calciphylaxis (NUC) – but it is considered extremely rare. Many factors are associated with the development of NUC, such as obesity, liver disease, elevated calcium–phosphorus product, decreased albumin level and systemic corticosteroid use. Nevertheless, the mechanisms underlying NUC pathogenesis are not fully understood. Recently, Weenig[3] reviewed the role of the predisposing factors and suggested that the putative risk factors result in increased levels of pro-inflammatory cytokines TNF-α, IL-1, and IL-6 together with activation of the nuclear factor κB, ultimately leading to vascular calcification.

We describe the first report of calciphylaxis in a patient seropositive for *Chagas* disease, which is known to lead to several immunological disturbances.

Case report

A 44-year-old woman with morbid obesity was initially admitted to our hospital due to dyspnea, cough, orthopnea, lower extremity edema, and pulmonary rales. Neither

* Corresponding author.
E-mail addresses: mvicco@santafe-conicet.gov.ar, mhvicco@outlook.com (M.H. Vicco).

0014-2565/$ – see front matter
http://dx.doi.org/10.1016/j.rce.2014.02.013

Please cite this article in press as: Vicco MH, et al. Non-uremic calciphylaxis and *Chagas* disease. Rev Clin Esp. 2014. http://dx.doi.org/10.1016/j.rce.2014.02.013

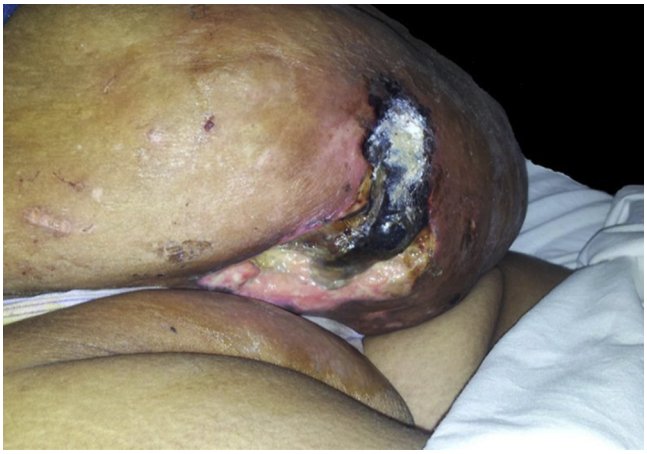

Figure 1 Large necrotic ulceration in the right inguinofemoral area surrounded by violaceous, indurated.

toxic habits nor history of cardiovascular, metabolic, pulmonary, or neurological diseases were recorded. Vital signs included blood pressure: 135/90 mmHg, heart rate: 110 heartbeats/min, respiration rate: 28 breath/min, oxygen saturation: 90%, and temperature: 37 °C. Routine laboratory tests showed normal hemogram as well as normal renal and liver function. The chest X-ray examination showed a cardiothoracic index >0.5, redistribution of pulmonary blood flow, and interstitial edema; the twelve-lead electrocardiogram revealed right bundle branch block and left anterior fascicular block. The 2D and M mode echocardiogram indicated mild enlarged atrial cavities and mild left ventricular hypertrophy with an ejection fraction of 45%; E-wave and A-wave reversal was noted at mitral diastolic flow and was consistent with impaired early diastolic filling. Because of the epidemiological history of *Chagas* disease, presence of specific antibodies for *Trypanosoma cruzi* was investigated. ELISA and indirect hemagglutination were performed using commercial kits (Wiener Lab, Rosario, Argentina), both yielding positive results. A diagnosis of congestive diastolic heart failure secondary to *Chagas* disease was made. During the next month she continued with heart failure symptoms and diuretic therapy was adjusted, resulting in considerable weight loss. Two months after the initial diagnosis, she was hospitalized again because of an anterior ulcerated painful lesion on her right inguinofemoral area for debridement (Fig. 1). Biopsy results of such lesion were consistent with calciphylaxis. Serum levels of calcium, phosphate, paratohormone and albumin were quantified, with results being within normal values. Despite treatment for this condition and multiple antibiotic therapies because of secondary infection, the lesion progressed to deep necrotic ulcerations extending to the hypogastrium area and right lower extremity. Anticoagulant therapies or specific treatment for *Chagas* disease were not indicated because the patient did not fit established recommendations. The patient died because of acute respiratory distress secondary to septicemia.

Discussion

To the best of our knowledge, this case is the first report of calciphylaxis associated with congestive diastolic heart failure secondary to *Chagas* disease. *Chagas* disease is caused by the obligate intracellular parasite *T. cruzi*, which affects millions of people worldwide. Up to 30% of the infected individuals ultimately develop clinically evident chronic cardiomyopathy or gastrointestinal disease.[4] We found two other published cases with calciphylaxis in patients with cardiomyopathy, normal renal function and a potentially reversible cause of cardiomyopathy.[5,6] In both cases, the skin lesion healed as the cardiac function improved; hence, the possibility of congestion from cardiac failure as playing a role in the poor healing of the wound was suggested. Nevertheless, in our patient the skin lesion progressed although she was hemodynamically stabilized. Considering there is little evidence about the association between heart failure and calciphylaxis, the different evolution of the wound of the present case may be related to the concomitant infection with *T. cruzi*, which is known to lead to several immunological disturbances.[7]

Weenig[3] suggested that calciphylaxis is the result of increased levels of pro-inflammatory cytokines, particularly TNF-α, IL-1, and IL-6, which promote the activation of the nuclear factor κB, ultimately leading to vascular calcification. In addition, it has recently been described that the infection with *T. cruzi* in the adipose tissue promotes the reduction of adiponectin plasma levels with a concomitant reduction in the expression of the peroxisome proliferator-activated receptor-gamma (PPAR-γ).[8] Both elements down-regulate the inflammatory response. PPAR-γ has the ability to inhibit inflammatory response by the down-modulating signal transduction pathways including direct interactions with NF-κB.[9] After infection with *T. cruzi*, the expression of pro-inflammatory cytokines, principally TNF-α, IL-1, and IL-6, in adipose tissue have been found to be elevated, because of persistent parasitism.[10]

Accordingly, we can conclude that co-infection with *T. cruzi* is likely to be a harmful factor for the course of calciphylaxis, due to the chronic inflammatory response induced by the persistence of *T. cruzi* in adipose tissue.

Conflict of interest

The author declares not having any conflict of interest.

Acknowledgments

This work was sponsored by the CONICET (Argentinean Research Council) and Universidad Nacional del Litoral, Argentina. M.H.V. and L.R. thank CONICET for their fellowship. I.M. and O.A.B. are members of the CONICET career.

References

1. Selye H. Calciphylaxis. Chicago: University of Chicago Press; 1962. p. 1.
2. Eleftheriadis T, Leivaditis K, Antoniadi G, Liakopoulos V. Calciphylaxis: current management and emerging therapies. J Nephrol Therapeutic S1. 2012, http://dx.doi.org/10.4172/2161-0959.S1-001.
3. Weenig RH. Pathogenesis of calciphylaxis: Hans Selye to nuclear factor kappa-B. J Am Acad Dermatol. 2008;58:458–71.

4. Vicco MH, Bontempi I, Ortiz S, Solari A, Bottasso OA, Marcipar I. Chronic Chagas disease with cardiodigestive involvement and the TcVI infective form of *Trypanosoma cruzi*. A case report. Parasitol Int. 2012;61:735–7.
5. Kolli S, Douglas J, Doumit E, Guglin M. Cardiomyopathy and calciphylaxis in a patient with normal renal function: a case report. Congest Heart Fail. 2010;16:71–2.
6. Almafragi A, Vandorpe J, Dujardin K. Calciphylaxis in a cardiac patient without renal disease. Acta Cardiol. 2009;64:91–3.
7. Ouaissi A, Cordeiro Da Silva A, Guevara AG, Borges M, Guilvard E. *Trypanosoma cruzi*-induced host immune system dysfunction: a rationale for parasite immunosuppressive factor(s) encoding gene targeting. J Biomed Biotechnol. 2001;1:11–7.
8. Nagajyothi F, Desruisseaux MS, Thiruvur N, Weiss LM, Braunstein VL, Albanese C, et al. *Trypanosoma cruzi* infection of cultured adipocytes results in an inflammatory phenotype. Obesity (Silver Spring). 2008;16:1992–7.
9. Chan MM, Evans KW, Moore AR, Fong D. Peroxisome proliferator-activated receptor (PPAR): balance for survival in parasitic infections. J Biomed Biotechnol. 2010;2010:828951 [Epub 10.02.10].
10. Hovsepian E, Penas F, Mirkin GA, Goren NB. Role of PPARs in *Trypanosoma cruzi* infection: implications for Chagas disease therapy. PPAR Res. 2012;2012:528435.

Please cite this article in press as: Vicco MH, et al. Non-uremic calciphylaxis and *Chagas* disease. Rev Clin Esp. 2014. http://dx.doi.org/10.1016/j.rce.2014.02.013