ISSN 0325-7541
INFORME BREVE
Revista Argentina de Microbiología (2011) 43: 48-50

# Ivermectin-related adverse clinical events in patients treated for *Mansonella ozzardi* infections

ALEJANDRO J. KROLEWIECKI[1, 2]*, SILVANA P. CAJAL[1, 3], CARLOS VILLALPANDO[1, 4], JOSÉ. F. GIL[1, 5]

[1]*Instituto de Investigaciones en Enfermedades Tropicales, Universidad Nacional de Salta, Sede regional Orán. San Ramón de la Nueva Orán, Argentina;* [2]*Fundación Huésped, Área de Investigaciones Clínicas. Buenos Aires, Argentina;*
[3]*Laboratorio de Enfermedades Tropicales, Hospital San Vicente de Paul, San Ramón de la Nueva Orán, Argentina;*
[4]*Gerencia sanitaria, Hospital San Vicente de Paul, San Ramón de la Nueva Orán, Argentina;*
[5]*Consejo Nacional de Investigaciones Científicas y Técnicas (CONICET), Argentina.*
**Correspondence. E-mail: alekrol@hotmail.com*

## ABSTRACT

We report the occurrence of serious reactions after treatment with oral ivermectin in two patients with *Mansonella ozzardi* infections. Both had systemic and respiratory symptoms and recovered without sequelae. Follow-up revealed clearance of microfilaremia in both cases, with relapse in one of them. These reactions are well described in the treatment of other filarial infections, but have not yet been reported in the treatment of *M. ozzardi*. We are now reporting the first such known reactions with this helminthiasis.

**Keywords:** *Mansonella ozzardi*, filariasis, ivermectin, safety

## RESUMEN

**Efectos clínicos adversos relacionados con ivermectina en pacientes tratados por infecciones con *Mansonella ozzarddi*.** Se informa la aparición de reacciones adversas graves con el tratamiento con ivermectina oral en dos pacientes con infección por *Mansonella ozzardi*. Ambos presentaron síntomas respiratorios y sistémicos y se recuperaron sin secuelas. El seguimiento mostró ausencia de microfilaremia en ambos casos, con recidiva en uno de ellos. Estas reacciones, bien conocidas durante el tratamiento de otras filariosis, se describen por primera vez con esta helmintiasis.

**Palabras clave:** *Mansonella ozzardi,* filariosis, ivermectina, seguridad

The filarial parasite *Mansonella ozzardi* causes infections in the tropical regions of Central and South America and the Caribbean. In Argentina, Biglieri and Araoz described the first cases in the Province of Tucumán in 1914 (1), at a time when no other human filarial infections were identified in this area. The Yungas, an ecological area characterized by tropical rainforest spreading from northwestern Argentina to southern Bolivia is endemic for *M. ozzardi*. *Culicoides lahillei* has been postulated as the principal vector in the area, with transmission occurring primarily during the wet season (9). A prevalence of *M. ozzardi* infection of 20.7% was reported (10) in El Oculto, a village with 80 inhabitants in the Yungas, in the Province of Salta (altitude 700 meters), Argentina.

Currently, ivermectin is the first-line drug for the treatment of filarial infections due to its efficacy and safety; over 400 million doses have been prescribed with excellent results and only a few cases with severe complications have been reported in the treatment of loiasis and onchocerciasis (2, 3). The side effects associated with treating patients infected with *Loa loa* are believed to be due to an exaggerated inflammatory response to the dying parasites (3). There is little experience in the treatment of infections due to *M. ozzardi*, which appears to be susceptible to ivermectin but resistant to diethylcarbamazine (7).

This report comments on two cases of serious adverse events related to ivermectin in the treatment of infections due to *M. ozzardi* in the department of Oran, Province of Salta, Argentina.

In the area of El Oculto in Salta (Figure 1), 10 symptomatic patients over a 15 year period agreed to the off-label use of a single dose of ivermectin (12 mg orally) for the treatment of *M. ozzardi* infection. All the patients were permanent residents of the community suffering from musculoskeletal symptoms. Diagnosis was made by the Knott's concentration test in blood obtained from venopuncture (5). Two patients developed serious adverse events following ivermectin (Securo, Valeant Argentina, 6 mg tablets) administration.

Case 1 was a 70 -year-old female with no remarkable medical history who presented with bilateral non-inflammatory edema of her knees and shoulder pain. She had lived her entire life in the Yungas and settled in El Oculto in 1970. Her peripheral blood smear stained with the Knott´s technique (Figure 2) revealed microfilaremia caused by *M. ozzardi*, with mild to moderate micro-

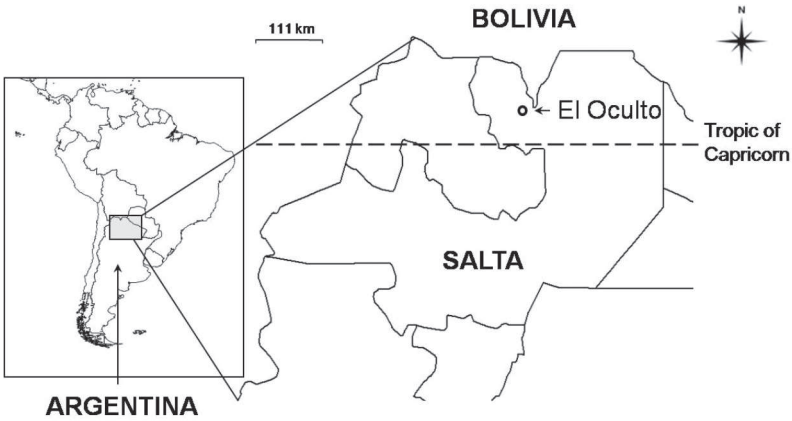


**Figure 1.** Geographic location of El Oculto in the Province of Salta, Argentina.

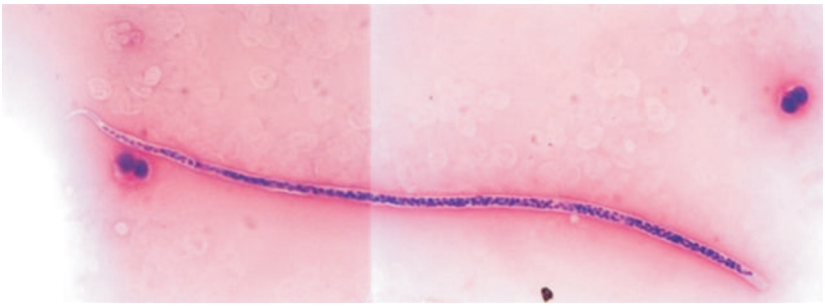

**Figure 2.** *Mansonella ozzardi* microfilaria seen in a Giemsa stained blood smear of patient case 1 prepared with the Knott's technique. 1,000 x magnification under immersion oil.

filaremia density. She was treated with 190 µg/kg of ivermectin. Within 12 hours of ivermectin administration, she started complaining of severe malaise, chills, fever and moderate dyspnea, which kept her bedridden. Her symptoms improved after 3 days and recovered without sequelae. The patient used non-concomitant medical or herbal therapies and recovered without further treatment. Blood smear examination with the Knott's technique revealed no microfilaremia 2 weeks after treatment, but a relapse was confirmed in a follow-up evaluation 5 years later. The patient was admitted to the local hospital and treated under medical supervision with ivermectin 200 µg/kg without any side effects. A follow-up evaluation 3 months after treatment revealed no microfilaremia.

Case 2 was a 68-year-old male without remarkable medical history, who presented with bilateral knee pain and generalized myalgias, and was found to have mild to moderate density of *M. ozzardi* microfilaria using the Knott's technique in his peripheral blood smear. He had lived in El Oculto since 1972. Six hours after receiving 158 µg/kg of ivermectin he began to have chills and malaise, followed by an episode of acute shortness of breath. He was assisted by his neighbors and recovered without sequelae after 2 days. He was not taking any concomitant therapy, but used local herbal infusions during his recovery. A follow-up examination revealed no microfilaremia in a blood smear 3 weeks after treatment.

Both cases were informed to the medical team in a follow-up visit to the village; three other patients who had lived in the endemic area for 25, 20 and 10 years, who were treated with ivermectin for *M. ozzardi* infections during the same period did not report any adverse events; they were of similar age and also had mild-moderate infection density in peripheral blood. Follow-up testing for microfilaremia performed between 30 and 60 days after therapy was negative in 2 of the 3 patients without adverse events; no follow-up smears were performed in the remaining patient.

We report the occurrence of serious adverse events in patients with infections due to *M. ozzardi* that resemble excessive forms of the expected Mazzotti's reaction seen upon treatment of other filarial infections; the lack of dermatologic findings in these cases might be related to the absence of the dermal localization that has been described for *M. ozzardi* (8). Due to the remoteness of

the patient's village, their reactions resolved without any medical attention or intervention.

In a bibliographic review of the published literature, the only report of events similar to our observations appears in the first report on the use of ivermectin against *M. ozzardi*, where a traveler with asthma and childhood allergies developed urticaria, fever and wheezing 12 hours after taking ivermectin. Her symptoms were rapidly controlled with epinephrine (7). In a clinical trial of ivermectin against *M. ozzardi* infections in Trinidad, 15% of the patients had severe reactions mostly consisting of fever, arthralgias and headache (4). Infection intensity, which is positively correlated with the severity of Mazzotti's reaction and other adverse events related to the treatment of filarial infections (6), could not be verified in our cases. In our group of patients, despite no statistically significant differences, patients with symptoms were those who had lived longer in the endemic area, which could be a surrogate marker for intensity of infection.

In summary, serious adverse events previously observed in the treatment of filarial infections could possibly be expected with *M. ozzardi* infections. Based on this report, and until further studies can be conducted, acute adverse events could be expected in patients with *M. ozzardi* and the convenience of its treatment weighed against the risk of adverse events. The availability of medical resources to treat adverse events (corticosteroids and epinephrine) and the case-by-case decision on the convenience of treatment appear to be required issues in the management of these patients.

## REFERENCES


1. Araoz R, Biglieri JM. Casos de microfilaria observados por primera vez en Tucumán. An Dept Nac Higiene 1915; 22: 151-9.
2. Boatin BA, Richards FO, Jr. Control of onchocerciasis. Adv Parasitol 2006; 61: 349-94.
3. Boussinesq M, Gardon J, Gardon-Wendel N, Chippaux JP. Clinical picture, epidemiology and outcome of *Loa*-associated serious adverse events related to mass ivermectin treatment of onchocerciasis in Cameroon. Filaria Journal 2003; 2 Suppl 1: S4.
4. Chadee DD, Tilluckdharry CG, Doon R, Rawlins SC, Narayansingh V, Ariyanayagam DC, Teelvcksingh S, Gaxotte P. Ivermectin treatment of mansonellosis in Blanchisseuse, Trinidad, West Indies. Ann Trop Med Parasitol 1996; 90: 645-9.
5. Garcia L. Procedures for detecting blood parasites. In: Diagnostic Medical Parasitology. Washington, DC., ASM Press, 2001, p. 829-47.
6. Mackenzie CD, Geary TG, Gerlach JA. Possible pathogenic pathways in the adverse clinical events seen following ivermectin administration to onchocerciasis patients. Filaria Journal 2003; 2 Suppl 1: S5.
7. Nutman TB, Nash TE, Ottesen EA. Ivermectin in the successful treatment of a patient with *Mansonella ozzardi* infection. J Infect Dis 1987; 156: 662-5.
8. Raccurt C, Lowrie RC, Jr., Boncy J, Katz SP. *Mansonella ozzardi* in Haiti. III. A comparison of the sensitivity of four sampling methods in detecting infections. Am J Trop Med Hyg 1982; 31: 275-9.
9. Shelley AJ, Coscaron S. Simuliid blackflies (Diptera: Simuliidae) and ceratopogonid midges (Diptera: Ceratopogonidae) as vectors of *Mansonella ozzardi* (Nematoda: Onchocercidae) in northern Argentina. Mem Inst Oswaldo Cruz 2001; 96: 451-8.
10. Taranto NJ, Castelli E. Detección de un foco de filariasis en el noroeste argentino. Rev Argent Microbiol 1988; 20: 49-51.


Recibido: 05/10/10 – Aceptado: 13/12/10