

# Wing myology of Caracaras (Aves, Falconiformes): muscular features associated with flight behavior

MARIANA BEATRIZ JULIETA PICASSO<sup>1</sup>\* & MARÍA CLELIA MOSTO<sup>1</sup>

<sup>1</sup> Museo de La Plata-Facultad de Ciencias Naturales y Museo, Universidad Nacional de La Plata – CONICET. Paseo del Bosque s/n, La Plata (1900), Buenos Aires, Argentina — \*corresponding author: mpicasso@fcnym.unlp.edu.ar

Accepted April 13, 2018.

Published online at [www.senckenberg.de/vertebrate-zoology](http://www.senckenberg.de/vertebrate-zoology) on May 28, 2018.

Editor in charge: Uwe Fritz

## Abstract

Caracaras (Aves, Falconiformes, Falconidae) are Neotropical diurnal raptors that belong to the subfamily Polyborinae. The forelimb myology of this group has not been comprehensively studied or compared with that of other Falconidae. Thus, the aims of this study were i) to describe the forelimb muscles of two species of Polyborinae (*Caracara plancus* and *Milvago chimango*), ii) to explore the possible relationship between muscular features and their function in flight behavior and iii) to compare the muscular features of these species with those of species of the subfamily Falconinae. To this end, the forelimb muscles of *C. plancus* (n=4) and *M. chimango* (n=4) were dissected. Additionally, to complement this data set, two specimens of *M. chimachima* were dissected. The mass of each muscle of one wing and its percentage with respect to the body mass were obtained. A total of 45 muscles were identified, and differences with respect to Falconinae were related to the presence of single or additional bellies. The total forelimb muscle mass represented between 7.68 and 10.26 % of the body mass. The muscle *pectoralis* represented ~5% of the body mass, followed by the muscles *scapulohumeralis caudalis* (0.64–0.79%), *deltoides major* (0.43–0.53%), *supracoracoideus* (0.34–0.38%) and *biceps brachii* (0.26–0.39%). The high values of these muscles are in agreement with their important function: they are involved in the downstroke and upstroke phases of the flapping flight. On the other hand, the muscles that seemed to contribute little to the mechanical power for flight presented low values that ranged between 0.01 and 0.25%. Comparison of the forelimb muscles of caracaras with published data on Falconinae species suggests that their muscular features might be associated with their type of flight, which is more erratic and less powerful than that of Falconinae.

## Key words

Forelimb morphology, Falconidae, Polyborinae.

## Introduction

Since flight is a demanding mode of locomotion, the wings of flying birds have numerous anatomical features to meet this demand (HEERS *et al.*, 2016). These include a complex and varied morphology comprising many muscles (between 45 and 50) (GEORGE & BERGER, 1966; RAIKOW, 1985), which generate and control their movements (VIDELER, 2006) and the different flight behaviors (e.g. flapping, gliding, hovering, etc.). Although the features of these muscles, i.e. number of bellies, relative development and mass, vary between taxa (HARTMAN, 1961; GEORGE & BERGER, 1966), this variability and its possible association with flight behavior have been scarcely investigated both in birds in general and particularly in

Falconiformes (see HARTMAN, 1961; MEYERS, 1992a, b; CORVIDAE *et al.*, 2006; HERTEL, MALDONADO & SUSTAITA, 2014; CANOVA *et al.*, 2015a, b, c).

Although the Falconidae have been classically grouped together with the Accipitridae (hawks, eagles, kites) due to their morphology, there is a general consensus that the Falconidae are phylogenetically distant from these other diurnal birds of prey (HACKETT, *et al.*, 2008; JARVIS *et al.*, 2014; PRUM *et al.*, 2015). The family Falconidae consists of three subfamilies, Polyborinae, Falconinae and Herpetotherinae, which show diversity in their locomotor behavior and diet. The Polyborinae (caracaras) are endemic to the New World and distinguished

as ambulatory birds that mostly forage by walking on the ground and in which flight is not as important as in the other two families (CADE & DIGBY, 1982; WHITE, *et al.*, 1994; FUCHS, *et al.* 2012). Moreover, the caracaras have an erratic and slow flight in which they alternate flapping and gliding (CANEVARI *et al.*, 1991; WHITE *et al.*, 1994). The caracaras also have a diverse diet: some genera like *Daptrius* and *Ibictier* are omnivorous and arboreal, whereas other genera, such as *Milvago*, *Caracara* and *Phalcoboenus*, are opportunistic, feeding on invertebrates, vertebrates, garbage and carrion (CANEVARI *et al.*, 1991; GRIN, 2018). In contrast, the Falconinae (cosmopolitan falcons) have a more diverse and complex flight behavior: they hunt in flight at high speeds to strike their prey (mainly birds and insects) and some species can also hover or soar (WHITE *et al.*, 1994; SUSTAITA, 2008). Finally, the Herpetotherinae (forest and laughing falcons) are secretive birds that inhabit the humid forests of the Neotropics and are poorly known (WHITE ET AL., 1994).

Despite these interesting flight variations, little is known about the forelimb myology of the Polyborinae, and previous research consists mainly on descriptive studies based on the Falconinae. BERGER (1956), studied the appendicular myology of *Polihierax semitorquatus* (Pygmy falcon), and described only 18 muscles of the wing. JOLLIE (1977), in his extensive study on birds of prey, briefly mentioned some muscles for the forelimbs of *Falco sparverius* (American kestrel) and *Polyborus cheriway*, with scarce information and few illustrations. MEYERS (1992a, 1996) studied the brachial and antebrachial muscles of *Falco sparverius*, being, to date, the most complete descriptive works on the forelimb myology of Falconidae. More recently, in a comparative framework with other non-Falconiformes bird species, CANOVA *et al.* (2015 a, b) studied some muscles of *Falco tinnunculus*. The only quantitative information regarding the mass of wing muscles was published by HARTMAN in 1961. However, these data do not refer to individual muscles, but to the entire wing, with the exception of the muscle *pectoralis* and the muscle *supracoracoideus*.

Thus, to expand our knowledge on the forelimb myology of the Polyborinae, the aims of the present study were i) to describe, photograph and illustrate the forelimb muscles of two species of Polyborinae (*Caracara plancus* and *Milvago chimango*), ii) to explore the possible relationship between the muscular features of these species and their function in flight behavior, and iii) to compare the muscular features of these species with those of species of the subfamily Falconinae.

## Materials and methods

**Specimens:** Healthy and unsexed adults of *Caracara plancus* (crested caracara, n=4), *Milvago chimango* (chimango caracara, n=4) and *Milvago chimachima* (yellow headed caracara, n=2) were used. The specimens

of *C. plancus* and *M. chimachima* were obtained from La Marcela farm (26°17035"S; 59°06067"W), Pirané, Formosa province, Argentina, with authorization of Ministerio de la Producción y Ambiente, Dirección de Fauna y Parques of Formosa Province (guía de tránsito n° 003384) during 2014. The specimens of *M. chimango* were obtained from Programa de Control de Aves en Rellenos Sanitarios y Areas Aledañas (ProCoA) in the province of Buenos Aires, Argentina, during 2013. This research complied with protocols approved by the animal care committee and adhered to the legal requirements of Argentina.

**Data collection:** The body mass of each specimen was weighed with a digital scale, except for that of the two specimens of *M. chimachima*, which was taken from DUNNING (2008). Then, the anterior corporal region was carefully separated from the rest of the body, without damaging the muscles. The hind limbs were studied in MOSTO ET AL. (2013; 2016). Each individual region was properly identified and stored in individual bags and frozen until it was studied. The left wing muscles were unilaterally dissected during the six months following storage. The wing muscles were defrosted, identified, photographed, carefully removed and weighed (both the fleshy and tendinous components) with a digital scale (with 0.01-g accuracy). The percentage of each muscle with respect to its body mass was calculated considering one wing. Also, the forelimb muscle mass was calculated as the sum of the individual muscles except the small muscles of the *manus* (*mm. abductor digiti majoris*, *extensor brevis alulae*, *abductor alulae*, *flexor digiti minoris*, *flexor alulae*, and *adductor alulae*), which give little mechanical power for flight (BIEWENER, 2011). Muscular mass data were explored considering the movements of the main bones and joints, including those of the muscles associated with the thoracic shoulder (*ossa cinguli*), the arm (*humerus*), the forearm (*ulna* and *radius*), the elbow (the *junctione cubiti*) and the wrist joint (*junctione carpi*). The main roles of the muscles during flight were determined following that described in the works of RAIKOW (1985), DIAL (1992) and VAZQUEZ (1995, Table 1).

The muscular description is the same in the three species and only the differences among them are mentioned. The interpretations about muscle mass were based only on the data obtained for *C. plancus* and *M. chimango*, given that the data available are more complete. Similarly, the interpretation about the small muscles of the *manus* and digits was based on the complete data obtained for *C. plancus*. Because of the low number of specimens of *M. chimachima*, the muscle mass data are provided only as complementary data. The *mm. subcoracoideus* and *subscapularis* were weighed together because of the common tendon of insertion, and the small *m. propatagialis p. caudalis* was not weighed. The anatomical nomenclature follows BAUMEL *et al.* (1993), and the abbreviations used in text are as follows: *m.* (muscle), *mm.* (muscles), and *p.* (pars).

**Table 1.** Wing muscles, the mean muscular mass (g), standard deviation (SD) and percentage of body mass (%BM), in brackets, the average body mass. DW/UP: humeral muscles that acts during the downstroke and upstroke respectively (following Dial, 1992). Muscle function according to: <sup>1</sup> Raikow (1985), <sup>2</sup> Dial (1992), <sup>3</sup> Vazquez (1995).

Muscle	Main function	Caracara plancus (1358.00 g)			Mitvago chimango (302.50g)			Mitvago chimachima (315.50g)		
		Mean	SD	%BM	Mean	SD	%BM	Mean	SD	%BM
<i>M. latissimus dorsi cranialis</i>	retracts the humerus <sup>1</sup>	0.83	0.27	0.06	0.10	0.04	0.03	0.22	0.13	0.07
<i>M. latissimus dorsi caudalis</i>		1.68	0.33	0.12	0.32	0.03	0.11	0.21	0.13	0.06
<i>M. rhomboideus (superficialis + profundus)</i>	stabilization of the thoracic girdle <sup>1</sup>	2.38	0.71	0.17	0.41	0.02	0.14	0.41	0.10	0.13
<i>M. serratus superficialis cranialis</i>	stabilization of the thoracic girdle <sup>1</sup>	0.37	0.09	0.03	0.09	0.04	0.03	0.05	0.01	0.02
<i>M. serratus superficialis caudalis</i>		1.10	0.38	0.08	0.22	0.07	0.07	0.21	0.06	0.06
<i>M. serratus profundus</i>		0.62	0.12	0.05	0.10	0.06	0.03	0.06	0.03	0.02
<i>M. pectoralis p. thoracica</i>	retracts and depress the humerus/DW <sup>2</sup>	71.97	10.73	5.27	15.99	2.00	5.28	15.26	0.79	4.84
<i>M. deltoideus propatagialis p. cranialis</i>	tense the propatagium <sup>2</sup>	2.59	1.41	0.19	0.38	0.10	0.12	0.36	0.01	0.11
<i>M. deltoideus propatagialis p. caudalis</i>	tense the propatagium <sup>2</sup>	—	—	—	—	—	—	—	—	—
<i>M. supracoracoideus</i>	elevates humerus/UP <sup>2</sup>	5.26	0.96	0.38	1.04	0.14	0.34	0.68	0.01	0.21
<i>M. deltoideus p. major</i>	elevation of humerus and wings/UP <sup>2</sup>	7.25	2.30	0.53	1.29	0.19	0.43	1.26	0.16	0.40
<i>M. deltoideus p. minor</i>	Protracts and elevates the humerus <sup>1</sup>	0.29	0.23	0.02	0.01	—	0.00	0.12	—	0.04
<i>M. coracobrachialis cranialis</i>	protracts and depress the humerus <sup>1</sup>	0.63	0.17	0.05	0.18	0.11	0.06	0.11	0.01	0.03
<i>M. coracobrachialis caudalis</i>	depress and rotates the humerus/DW <sup>1</sup>	2.59	1.37	0.19	0.38	0.09	0.13	0.29	0.06	0.09
<i>M. scapulohumeralis caudalis</i>	retracts the humerus, rotation of the wing/DW <sup>2</sup>	1.08	0.33	0.79	0.11	0.26	0.64	0.04	0.20	—
<i>M. scapulohumeralis cranialis</i>	retracts the humerus <sup>1</sup>	0.01	0.00	0.02	0.01	0.01	—	—	—	—
<i>M. subscapularis</i>	retracts the humerus/DW <sup>2</sup>	2.31	0.75	0.17	0.53	0.03	0.18	0.41	0.04	0.13
<i>M. subcoracoideus</i>	depress and rotates the humerus dorsally/DW <sup>2</sup>	4.16	1.20	0.30	0.63	0.15	0.21	0.64	0.11	0.20
<i>M. scapulothoriceps</i>	stabilizes the elbow/UP <sup>2</sup>	4.47	1.20	0.33	0.74	0.05	0.25	0.64	0.05	0.20
<i>M. humerotriceps</i>	extends the elbow/DW <sup>2</sup>	5.34	1.11	0.39	0.80	0.08	0.26	0.94	0.21	0.30
<i>M. biceps brachii</i>	stabilizes the elbow, flex the forearm/DW <sup>2</sup>	0.49	0.15	0.04	0.08	0.02	0.03	0.08	—	0.03
<i>M. brachialis</i>	flex the elbow <sup>1</sup>	0.97	0.27	0.07	0.15	0.03	0.05	0.12	0.00	0.04
<i>M. pronator superficialis</i>	ventral rotation of the wing <sup>2</sup>	1.94	0.39	0.14	0.36	0.04	0.12	0.31	0.06	0.10
<i>M. pronator profundus</i>	ventral rotation of forearm <sup>1</sup>	0.66	0.15	0.05	0.14	0.04	0.05	0.11	0.04	0.03
<i>M. flexor digitorum superficialis</i>	flex the wrist and extend digiti majoris <sup>3</sup>	2.25	0.72	0.17	0.49	0.07	0.16	0.43	0.09	0.13
<i>M. flexor carpi ulnaris</i>	flex the wrist <sup>2</sup>	0.72	0.20	0.05	0.16	0.03	0.05	0.12	0.00	0.04
<i>M. flexor digitorum profundus</i>	flex the wrist <sup>3</sup>	0.58	0.12	0.04	0.12	0.01	0.04	0.12	0.04	0.04
<i>M. ulno-metacarpalis ventralis</i>	flex and pronates the wrist <sup>3</sup>	0.31	0.08	0.02	0.06	0.02	0.02	0.02	—	0.01
<i>M. supinator</i>	Rotates forearm <sup>1</sup>	2.43	0.41	0.18	0.42	0.05	0.14	0.43	0.03	0.14
<i>M. extensor carpi radialis</i>	extends the wrist <sup>2</sup>	0.69	0.13	0.05	0.14	0.02	0.04	0.11	0.01	0.03
<i>M. extensor digitorum communis</i>	wrist flexion and stabilization <sup>3</sup>	0.77	0.23	0.06	0.14	0.02	0.05	0.11	0.02	0.03
<i>M. extensor carpi ulnaris</i>	flex the wrist <sup>3</sup>	1.02	0.21	0.07	0.19	0.02	0.06	0.13	0.01	0.04
<i>M. ectepicondilo ulnaris</i>	elevates forearm <sup>1</sup>	0.83	0.31	0.06	0.15	0.02	0.05	0.13	0.01	0.04
<i>M. extensor longus ulnae</i>	extends the wrist <sup>3</sup>	0.53	0.11	0.04	0.12	0.02	0.04	0.08	0.03	0.03
<i>M. extensor longus digiti majoris</i>	extends digiti majoris <sup>3</sup>	—	—	—	—	—	—	—	—	—

Table 1 continued.

Muscle	Main function	Caracara plancus (1358.00 g)			Milvago chimango (302.50g)			Milvago chimachima (315.50g)		
		Mean	SD	%BM	Mean	SD	%BM	Mean	SD	%BM
<i>M. ulnometacarpalis dorsalis</i>	flex the wrist <sup>3</sup>	0.57	0.07	0.04	0.06	0.00	0.02	0.05	0.03	0.02
<i>M. interosseus dorsalis</i>	elevates digiti majoris <sup>3</sup>	0.19	0.03	0.01	0.04	—	0.01	0.04	—	0.01
<i>M. interosseus ventralis</i>	flex digiti majorisb <sup>3</sup>	0.17	0.03	0.01	0.05	0.02	0.02	0.03	—	0.01
<i>M. extensor brevis alulae</i>	extends alular digit <sup>3</sup>	0.06	0.05	0.01	—	—	—	—	—	—
<i>M. abductor alulae</i>	extends and depress alular digit <sup>3</sup>	0.09	0.02	0.01	—	—	—	—	—	—
<i>M. flexor alulae</i>	depress alular digit <sup>3</sup>	0.07	0.06	0.01	—	—	—	—	—	—
<i>M. adductor alulae</i>	flex alular digit <sup>3</sup>	0.22	0.08	0.02	—	—	—	—	—	—
<i>M. abductor digiti majoris</i>	extends digiti majoris <sup>3</sup>	0.14	0.11	0.01	—	—	—	—	—	—
<i>M. flexor digiti minoris</i>	flex digiti majoris and minoris <sup>3</sup>	0.08	0.02	0.01	—	—	—	—	—	—
<b>Forelimb mass</b>		130.62	—	10.26	24.27	—	7.68	—	—	—
<b>Upstroke muscles</b>		16.67	—	1.22	2.96	—	0.98	—	—	—
<b>Downstroke muscles</b>		87.76	—	7.14	18.56	—	6.73	—	—	—

## Results

### Muscular description

The *m. latissimus dorsi* (Fig. 1A–D) has two independent portions: the *p. cranialis* and the *p. caudalis*. The *p. cranialis* (Fig. 1A–C) is a fleshy band-shaped muscle that originates on the *spinous process* of the *cervical vertebrae* and inserts into the medial facet of the *corpus humeri*, covering the second proximal quarter (Fig. 2A).

The *p. caudalis* (Fig. 1A–D) is also a fleshy band-shaped muscle, although wider and thicker than the *p. cranialis*, which is situated on the *m. rhomboideus superficialis*. It inserts into the *humerus* via a tendon (Fig. 2A), which is common to that of the origin of the *m. scapulotriceps*.

The *m. rhomboideus superficialis* (Fig. 1A–D) is a fleshy muscle with two distinct and contiguous fleshy portions (cranial and caudal) that originate on the last *cervical vertebrae*. The cranial portion is square-shaped and inserts into the first quarter of the *scapula* (Fig. 2C), whereas the caudal portion is wider than the cranial one and inserts into the *scapula*, reaching the region of the *angulus subterminalis* (*sensu* LIVEZEY & SUZY, 2006; Fig. 2C).

The *m. rhomboideus profundus* (Fig. 2D) is a fleshy muscle that originates on the cervical vertebrae and inserts into the medial surface of the scapula. It is located right beneath the *m. rhomboideus superficialis*, from which it is difficult to separate.

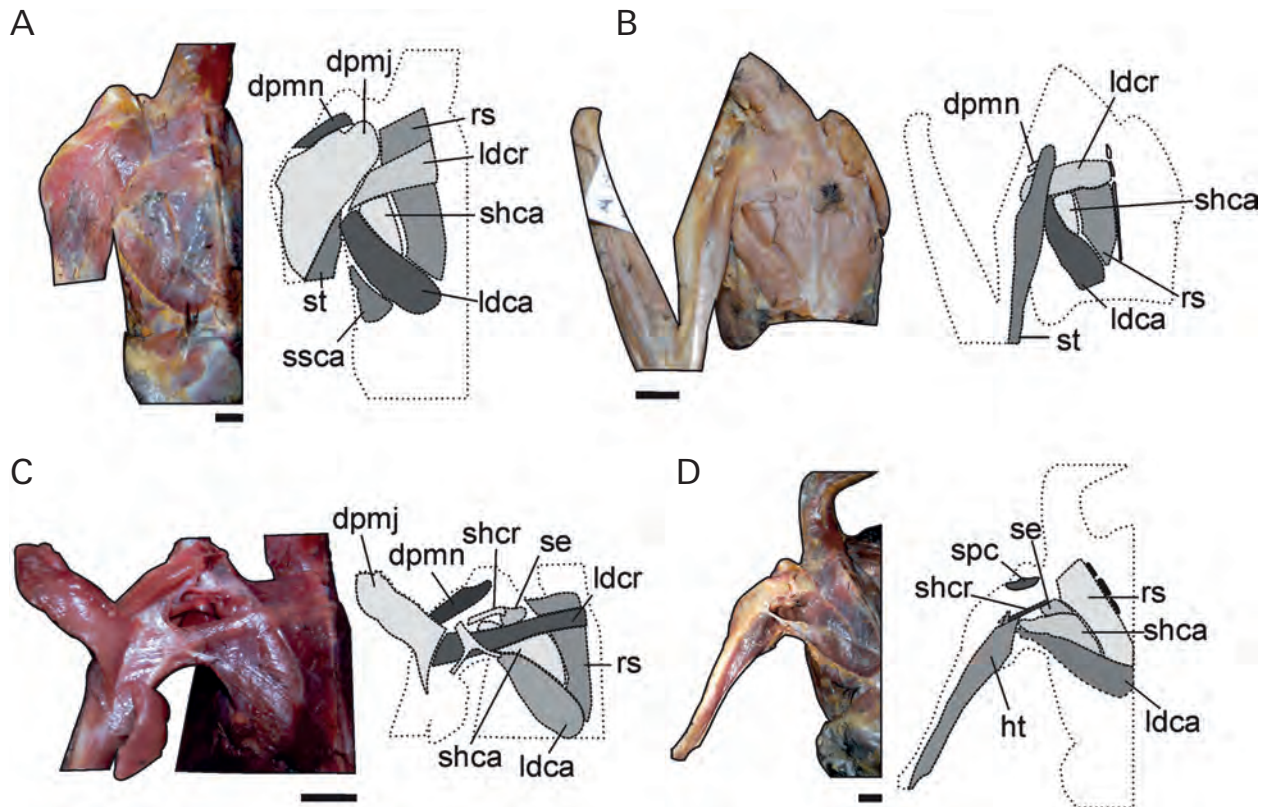
The *m. serratus superficialis* (Fig. 1A) consists of two independent bellies: the *p. cranialis* and the *p. caudalis*. The *p. cranialis* is a fleshy band-shaped muscle that originates on the ribs near the *processus uncinatus*, and attaches on the cranial half of the *scapula* between the two bellies of the *m. subscapularis* (Fig. 2D). The *p. caudalis* is a fleshy, broad and flat muscle that originates on the caudal ribs, covering the *processus uncinatus*, and inserts into the medial surface and ventral end of the *scapula*, on the last caudal third (Fig. 2C).

The *m. serratus profundus* is a fleshy and flat muscle that originates on the first ribs and inserts into the medial surface at the third caudal quarter of the *scapula* (Fig. 2D).

The *m. pectoralis p. thoracica* (Fig. 3A, C) is a fleshy well-developed muscle that originates on various structures: the *carina sterni*, the ventral aspect of the *clavicula* (Fig. 2B) and the membranes *sternocoracoclavicularis* and *cristoclavicularis*. The muscle inserts into the proximal region of the *corpus humeri* on the *crista deltopectoralis* (Fig. 2B).

The *m. pectoralis propatagialis p. longus* (Fig. 4A, B) is a small, fleshy and elongated portion of the muscle *pectoralis p. thoracica*, with an elastic tendon that penetrates the *propatagium* and gives support to its leading edge. The tendon inserts into the thick aponeurosis that cov-





**Fig. 1.** Image and schematic drawings of the superficial muscles of shoulder and proximal *humerus* of *Caracara plancus* (A) and (D), *Milvago chimachima* (B) and *Milvago chimango* (C). Abbreviations: (dpmj) *M. deltoideus p. major*, (dpmn) *M. deltoideus p. minor*, (ht) *M. humerotriceps*, (ldca) *M. latissimus dorsi caudalis*, (ldcr) *M. latissimus dorsi cranialis*, (rs) *M. rhomboideus* (superficialis + profundus), (st) *M. scapulotriceps*, (se) *M. subscapularis*, (shca) *M. scapulohumeralis caudalis*, (shcr) *M. scapulohumeralis cranialis*, (spc) *M. supracoracoideus*, (ssca) *M. serratus superficialis caudalis*. Scale bars: 1 cm.

ers the *carpometacarpus*, on the region of the *processus extensorius*.

The *m. deltoideus propatagialis p. cranialis* (Fig. 4A–B) is a well-developed muscle that originates fleshy on the dorsal aspect of the *furcula* (Fig. 3B). The belly gives rise to a tendon that penetrates the *patagium* and bifurcates into two tendons, both of which insert into the tendon of origin of the *m. extensor metacarpi radialis*.

The *m. deltoideus propatagialis p. caudalis* (Fig. 4B) is a small fleshy cranial portion of the *m. deltoideus propatagialis p. cranialis*, from which it is separated by a thin tendinous raphe. The muscle has a short tendon that fuses to the elastic tendon of the *m. pectoralis propatagialis p. longus*.

The *m. supracoracoideus* (Fig. 5A–B) is a well-developed muscle that lies deep to the *m. pectoralis*, with a fleshy origin on the cranial half of the *sternum* (Fig. 3A), along the *coracoideum* (Fig. 3E) and on the *membrane sternoclavicularis*. The muscle passes through the *canalis triosseus* and inserts into the proximal end of the *humerus*, on the *tuberculum dorsale* (Fig. 2A).

The *m. deltoideus p. major* (Figs. 1A–B and 4A) has two bellies that join together and insert via a tendon along the *crista deltopectoralis* of the *humerus* (Fig. 2A). The

*p. cranialis* originates fleshy on the *fibrocartilage humeroscapularis* and adjacent ligaments. The *p. caudalis* is fleshy and originates on the *scapula* (Fig. 2D).

The *m. deltoideus p. minor* (Fig. 1A, B) is a poorly developed muscle located on the tendon of insertion of the *m. supracoracoideus*.

The *m. coracobrachialis cranialis* (Fig. 5B) is a short fleshy muscle that originates on the *coracoideum*, on the *extremitas omalis coracoidei* (Fig. 3E). The muscle crosses the joint and inserts into the *extremitas proximalis humeri* (Fig. 2B).

The *m. coracobrachialis caudalis* (Fig. 5A–B) originates fleshy on the sternal region, proximal to the *coracoideum* and the adjacent *sternum* (Fig. 3A, E). This muscle inserts by a tendon on the *tuberculum ventrale* of the *humerus* (Fig. 2A).

The *m. scapulohumeralis cranialis* (Fig. 1C–D) is a small fleshy muscle that originates on the dorsal surface of the *scapula* and inserts into the *humerus* near the *foramen pneumaticum*, dividing the *m. humerotriceps* into internal and external bellies.

The *m. scapulohumeralis caudalis* (Figs. 1A and 5A–B) has a fleshy origin along the caudal half of the *scapula*.

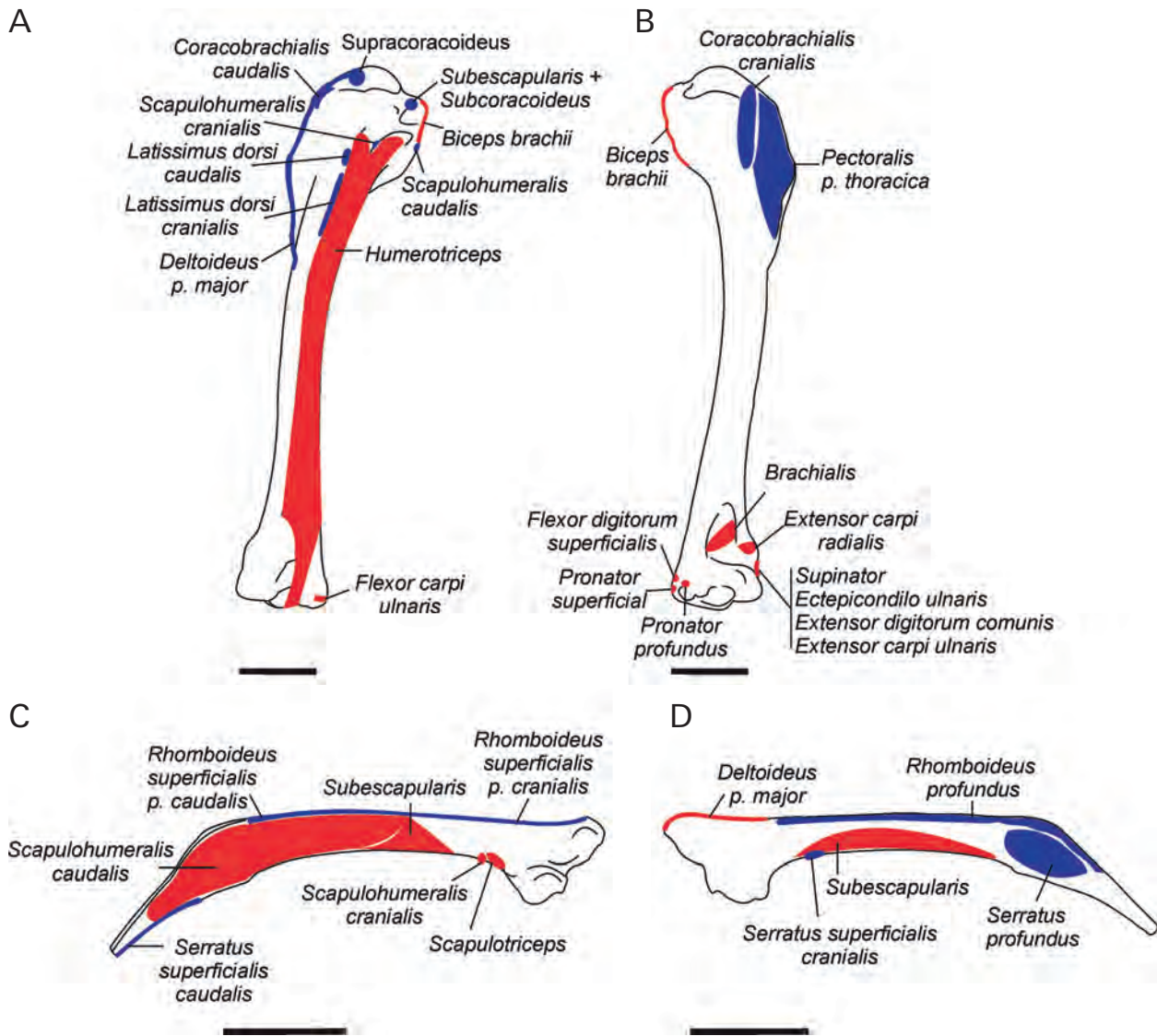


Fig. 2. Muscular maps showing the sites of origin (red) and insertion (blue) of *humerus* in (A) dorsal and (B) ventral aspect; *scapula* in dorsal (C) and ventral (D) aspect. Scale bars: 1 cm.

The insertion is via a tendon on the caudal aspect of the *foramen pneumaticum* of the *humerus*.

The *m. subscapularis* (Figs. 1D and 5C) has two fleshy portions, the *caput laterale* and the *caput mediale*, with the *m. serratus superficialis* between them. The *caput laterale* originates on the dorsal surface of the *scapula* (Fig. 2C), whereas the *caput mediale* originates on the ventral surface (Fig. 2D). Both portions join and give rise to a common tendon that inserts into the *tuberculum ventrale* of the *humerus* along with the tendon of the *m. subcoracoideus* (Fig. 2A).

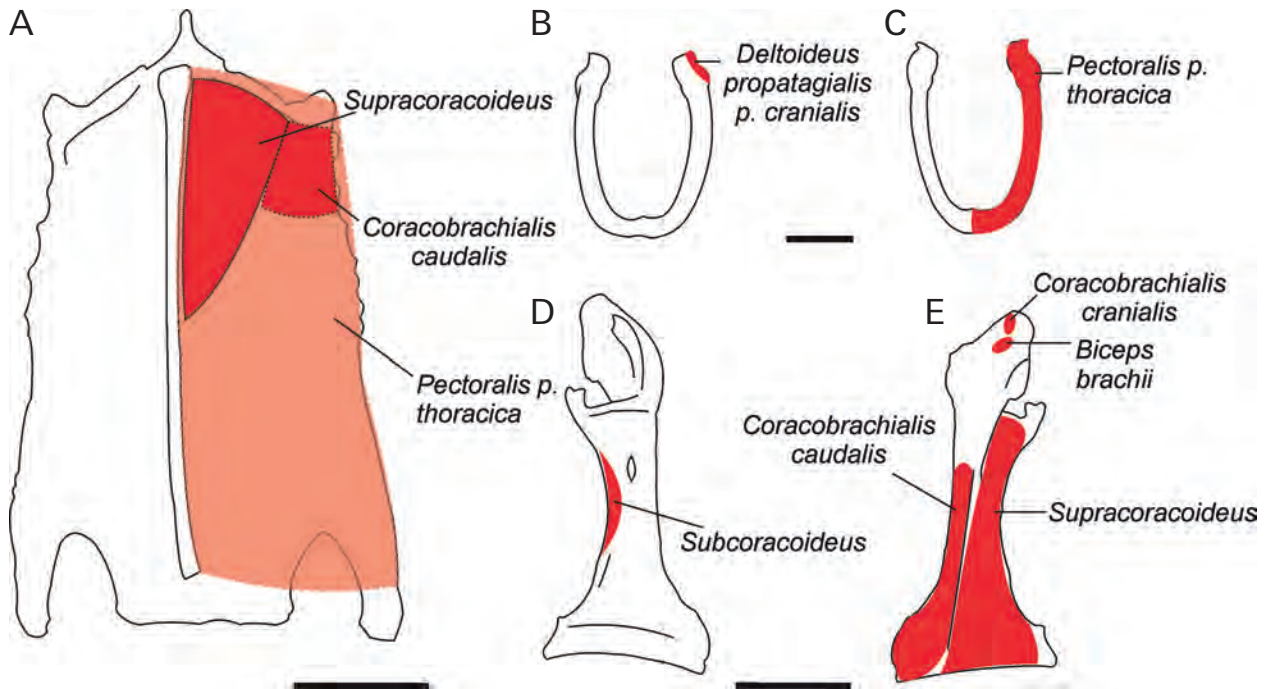
The *m. subcoracoideus* (Fig. 5A–C) is a fleshy muscle located on the medial aspect of the *coracoideum*, originated on the medial surface of the *corpus coracoidei* (Fig. 3D). It inserts by a common tendon into with the *m. subscapularis* on the *tuberculum ventrale* of the *humerus* to (Fig. 2A).

The *m. scapulotriceps* (Figs. 1A–B and 5A) originates from an aponeurosis on the *scapula*, immediately posterior to the joint with the *coracoideum* (Fig. 2C). The fleshy portion shares the aponeurosis with the *m. latissimus dorsi p. caudalis*. The muscle inserts into the *ulna* on the *impressio m. scapulotricepitis* via a tendon (Fig. 6A).

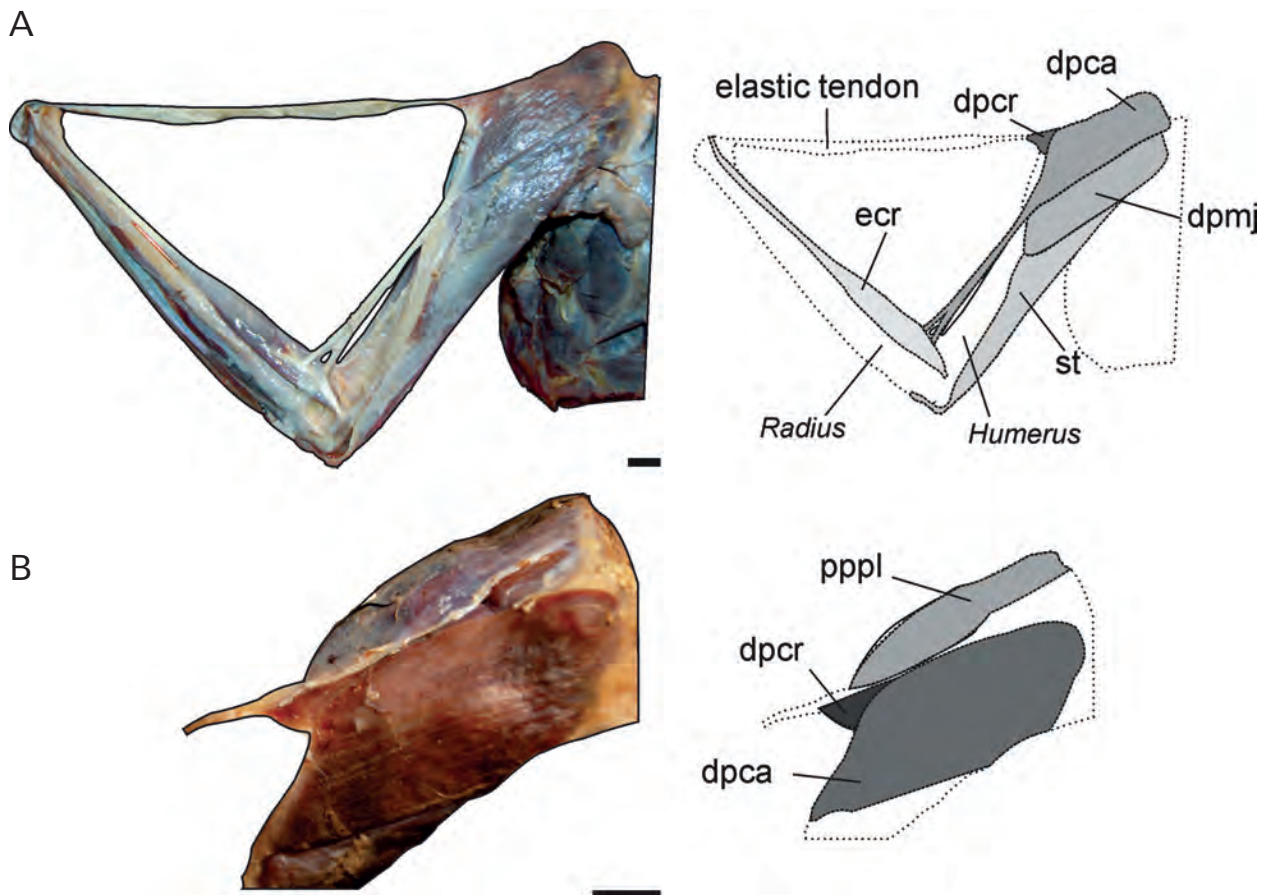
The *m. humerotriceps* (Fig. 1D) originates fleshy on the *fossa pneumaticipitalis* and the *corpus humeri* (Fig. 2A). It inserts both fleshy and tendinous into the *olecranon* (Fig. 6A).

The *m. biceps brachii* (Figs. 5B and 7A) has a strong and wide tendon originated on the *extremitas omalis* of the *coracoideum* (Fig. 3E) and on the *crista bicipitalis* of the *humerus* (Fig. 2B). The muscle continues fleshy along the *corpus humeri* until the tendon of insertion approaches the *ulna* and *radius*, and then splits into two tendons, one of which inserts into the proximal end of the *ulna* and the other into the *radius* (Fig. 6B).

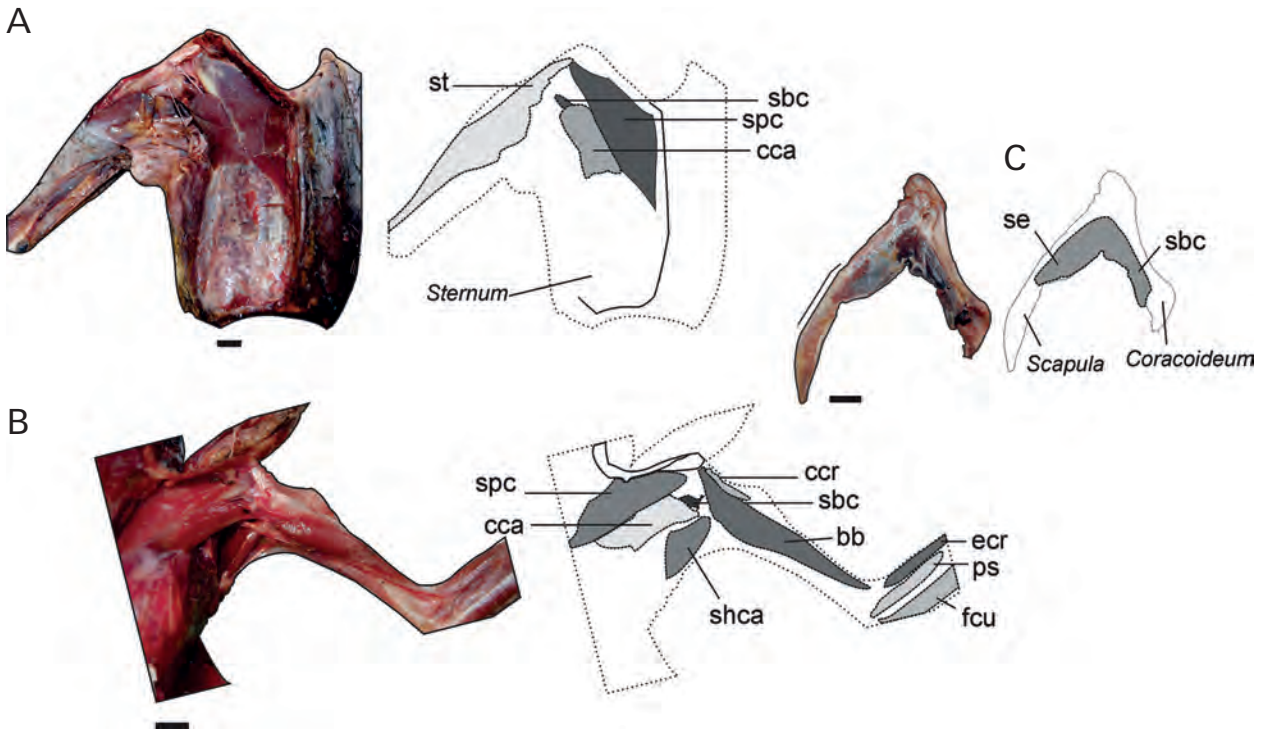




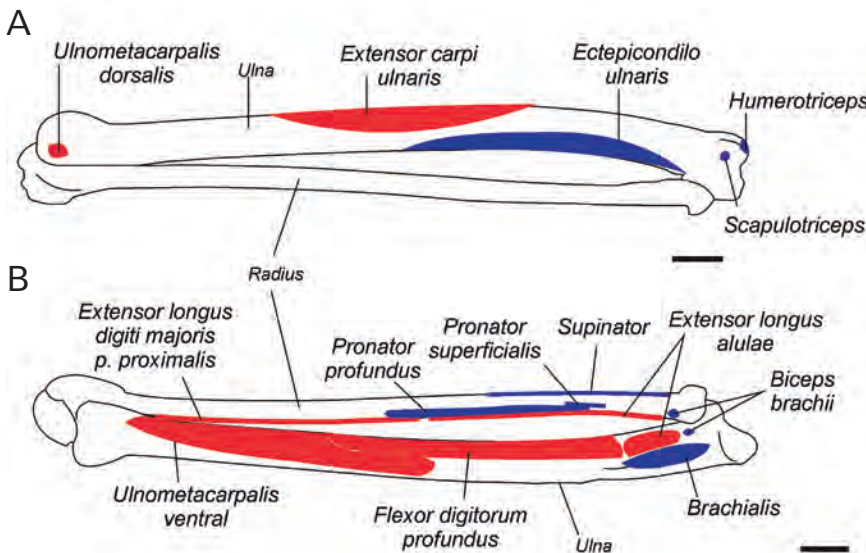
**Fig. 3.** Muscular maps showing the sites of origin in (A) the ventral aspect of the *sternum*, (B) and (C) cranial and caudal aspect respectively of the *clavicula*, (D) and (E) dorsal and ventral aspect respectively of the *coracoideum*. Scale bars: 1cm.



**Fig. 4.** Image and schematic drawings of *Caracara plancus* showing (A) the superficial dorsal muscles of the arm and forearm, (B) detailed view showing the small *M. deltoideus p. propatagialis p. cranialis*. Abbreviations: (dpmj) *M. deltoideus p. major*, (ecr) *M. extensor carpi radialis*, (st) *M. scapulotriceps*, (dpca) *M. deltoideus p. propatagialis p. caudalis*, (dpcr) *M. deltoideus propatagialis p. cranialis*, (pppl) *M. pectoralis propatagialis p. longus*. Scale bars: 1cm.



**Fig. 5.** Image and schematic drawings showing the ventral and deep muscles of the (A) *sternum*, (B) proximal *humerus*, (C) *scapula* and *coracoideu*, (A,C) *Caracara plancus*; (B) *Milvago chimango*. Abbreviations: (bb) *M. biceps brachii*, (ccr) *M. coracobrachialis cranialis*, (cca) *M. coracobrachialis caudalis*, (ecr) *M. extensor carpi radialis*, (fcu) *M. flexor carpi ulnaris*, (ps) *M. pronator superficialis*, (sbc) *M. subcoracoideus*, (se) *M. subscapularis*, (shca) *M. scapulohumeralis caudalis*, (spc) *M. supracoracoideus*, (st) *M. scapulothriceps*. Scale bars: 1cm.



**Fig. 6.** Muscular maps showing the sites of origin (red) and insertion (blue) of the forearm, (A) dorsal aspect, (B) ventral aspect. Scale bars: 1cm.

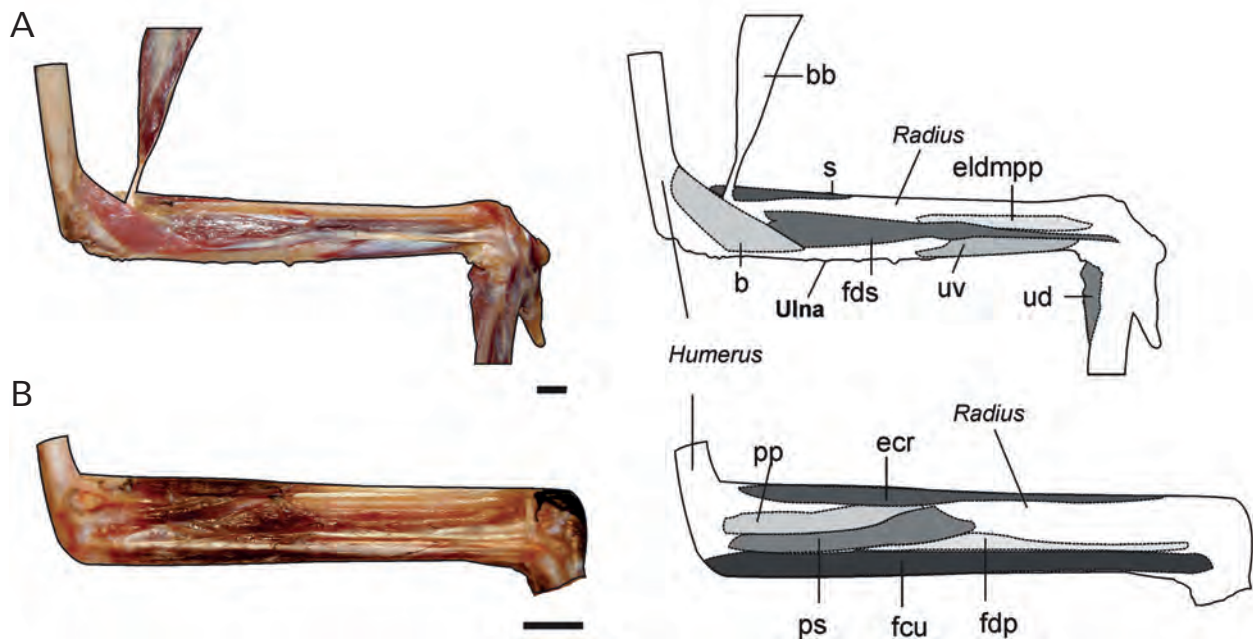
The *m. brachialis* (Fig. 7A) is a short and fleshy muscle that originates on the *fossa brachialis* of the distal *humerus*, (Fig. 2B) and inserts into the *depressio m. brachialis* of the *ulna* (Fig. 6B).

The *m. pronator superficialis* (Figs. 5C and 7B) originates from a short and strong tendon on the distal *humerus* (Fig. 2B). It inserts both fleshy and tendinous into the proximal *radius* (Fig. 6B). In *Caracara plancus*, the muscle originates both aponeurotic and fleshy.

The *m. pronator profundus* (Fig. 7B) has a tendinous origin on the *epicondylus ventralis* of the *humerus* (Fig. 2B). The insertion is fleshy along the proximal third of the *corpus radii* (Fig. 6B). In *Caracara plancus*, the insertion reaches half way on the *corpus radii*.

The *m. flexor digitorum superficialis* (Fig. 7A) is a thin muscle that originates tendinous on the *epicondylus ventralis* of the *humerus* (Fig. 2B). The belly gives rise to a tendon that inserts into the proximal phalanx of the *digiti*





**Fig. 7.** Image and schematic drawings of the ventral aspect of the forearm showing (A) superficial and (B) deep muscles in *Caracara plancus*. Abbreviations: (b) *M. brachialis*, (bb) *M. biceps brachii*, (ecr) *M. extensor carpi radialis*, (eldmpp) *M. extensor longus digiti majoris*, (fcu) *M. flexor carpi ulnaris*, (fds) *M. flexor digitorum superficialis*, (fdp) *M. flexor digitorum profundus*, (pp) *M. pronator profundus*, (ps) *M. pronator superficialis*, (s) *M. supinator*, (ud) *M. ulnometacarpalis dorsalis*, (uv) *M. ulno-metacarpalis ventralis*. Scale bars: 1cm.

*majoris* (Fig. 8A). This tendon runs along the cranio-ventral edge of the *carpometacarpus* along with the tendon of the *m. flexor digitorum profundus*.

The *m. flexor carpi ulnaris* (Figs. 5C and 7B) is a well-developed muscle with a tendinous origin on the *epicondylus ventralis* of the *humeri* (Fig. 2A). The fusiform belly gives rise to a tendon that inserts into the *os carpal ulnare* (Fig. 8A). In *Caracara plancus*, the tendon of origin is strong.

The *m. flexor digitorum profundus* (Fig. 7B) has a fusiform belly that originates fleshy on the first third of the *ulna* (Fig. 6B), and a small part that also originates on the *m. brachialis* (Fig. 6B). It inserts into the distal phalanx of the *digiti majoris* via a tendon that runs along the *carpometacarpus*, where it is ossified (Fig. 8A).

The *m. ulnometacarpalis ventralis* (Fig. 7A) has a fleshy origin on the ventral side of the *ulna* (Fig. 6B). It inserts into the dorsal aspect of the proximal *carpometacarpus* near the origin of *m. extensor brevis alulae* via a tendon (Fig. 8B).

The *m. supinator* (Fig. 7A) is a short muscle with a tendinous origin on the *epicondylus lateralis* of the *humerus* (Fig. 2B), sharing a common origin with the *m. extensor digiti communis* and the *m. extensor metacarpalis cubitalis*. It inserts fleshy into the first quarter of the *corpus radii* (Fig. 6B). The *m. extensor carpi radialis* (Figs. 4A, 5B, 7B, and 9A) is a fusiform muscle with both a fleshy and tendinous origin. It originates on the *processus supracondylaris dorsalis* of the distal *humerus* (Fig. 2B).

It inserts tendinous into the *processus extensorius* of the *carpometacarpus* (Fig. 8A).

The *m. extensor digitorum communis* (Fig. 9A) is a V-shaped muscle with an aponeurotic origin on the *epicondylus dorsalis* of the *humerus* (Fig. 2B). The belly is fusiform and the insertion is by a bifurcated tendon on two digits. The short tendon inserts into the phalanx of the *digiti alulae* (Fig. 8B), whereas the long tendon passes through the *sulcus tendineus* of the *carpometacarpus* and inserts into the base of the proximal phalanx of the *digiti majoris* (Fig. 8B).

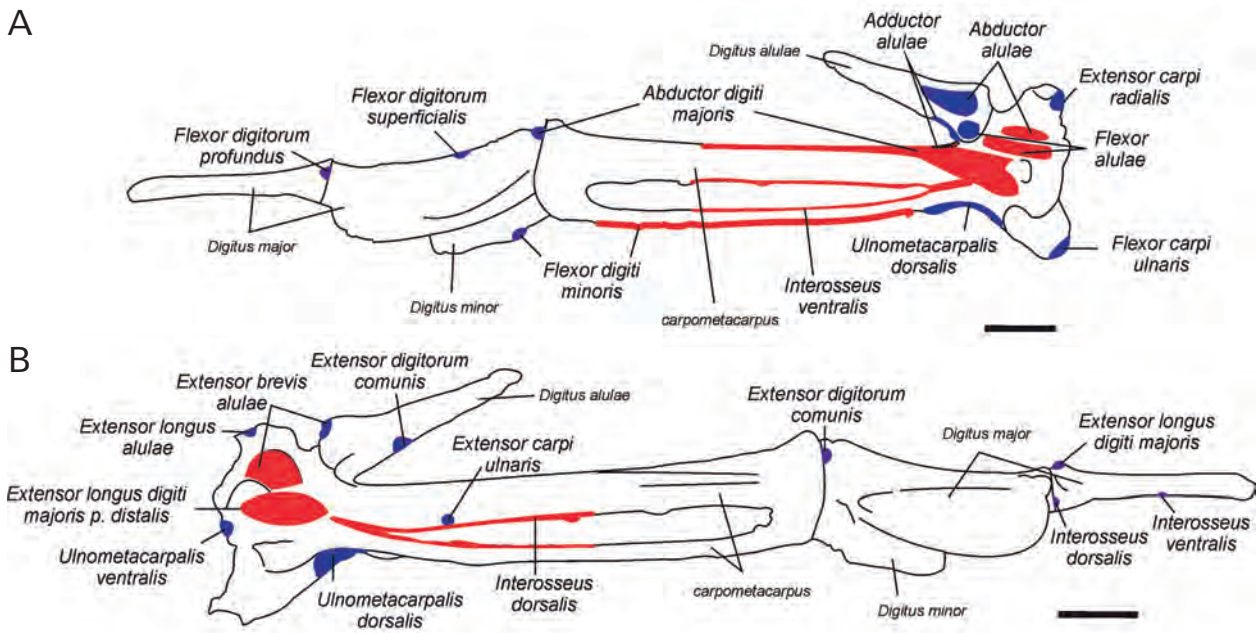
The next four muscles have a common origin on the *epicondylus lateralis* of the *humerus* (Fig. 2B).

The *m. extensor carpi ulnaris* (Fig. 9A) originates on the surface of the *m. ectepicondylo-ulnaris* via a tendon (Fig. 2B). The belly is attached to the *corpus ulnae* (Fig. 6A) until the third quarter, where the tendon of insertion originates and finally inserts into the proximal *carpometacarpus* (Fig. 8B).

The *m. ectepicondylo-ulnaris* (Fig. 9B) has a tendinous origin on the *epicondylus lateralis* of the *humerus* (Fig. 2B) and inserts fleshy into the *ulna* (Fig. 6A).

The *m. extensor longus alulae* (Fig. 9B) originates fleshy on the *radius* (Fig. 6B) and inserts into the *processus extensorius* of the *carpometacarpus* via a tendon (Fig. 8B).

The *m. extensor longus digiti majoris* (Figs. 7A and 9A) has two portions: the *p. proximalis* and the *p. distalis*.



**Fig. 8.** Muscular maps showing the sites of origin (red) and insertion (blue) of the *carpometacarpus* and digits in (A) ventral and (B) dorsal aspect. Scale bars: 1cm.

The *p. proximalis* originates fleshy on the distal region of the medial surface of the *radius* (Fig. 6B). The muscle becomes tendinous near the wrist joint and inserts into a tubercle of the terminal phalanx of the *digiti majoris* (Fig. 8B). The *p. distalis* (Fig. 10B) is small and fleshy and originates on the proximal region of the *carpometacarpus*. The muscle joins the tendon of the *p. proximalis* by a short tendon.

The *m. ulnometacarpalis dorsalis* (Figs. 7A and 10A–B) has a superficial belly with a triangular shape that originates on the distal *ulna* via a tendon (Fig. 6A). The muscle inserts fleshy into the surface of the proximal *carpometacarpus* near the *os metacarpale minus* (Fig. 8A–B).

The *m. interosseus dorsalis* (Fig. 10B) is a small muscle with a fleshy origin on the edges of the *spatium intermetacarpale* (Fig. 8B). It inserts into the proximal end of the distal phalanx of the *digiti majoris* by a long tendon (Fig. 8B). In *Caracara plancus*, some fibers insert into the proximal angle of the *spatium intermetacarpale*.

The *m. interosseus ventralis* (Fig. 10A) originates fleshy on the edges of the *spatium intermetacarpale* (Fig. 8A) and inserts into the end of the distal phalanx of the *digiti majoris* via a tendon (Fig. 8B).

The *m. extensor brevis alulae* (Fig. 10B) is a small muscle with a fleshy origin on the dorsal surface of the *carpometacarpus* (Fig. 8B), near the *processus extensorius*. It inserts into the proximal region of the alular phalanx via a tendon (Fig. 8B).

The *m. abductor alulae* (Fig. 10A) is an entirely fleshy muscle located on the ventral surface of the *manus*, with a superficial and a deep belly. The superficial belly originates fleshy on the tendon of insertion of the *m. extensor*

*carpi radialis*, whereas the deep belly is located beneath the superficial belly. Both parts are closely related and go through the *processus extensorius* of the *carpometacarpus* and ligaments of the wrist joint and insert into the ventral aspect of the *digiti alulae* (Fig. 8A).

The *m. flexor alulae* (Fig. 10A) is a small and fleshy muscle located on the ventral surface of the *manus*. It originates on the proximal region of the *carpometacarpus* (Fig. 8A) and inserts into the proximal region of the phalanx of the *digiti alulae* (Fig. 8A).

The *m. adductor alulae* (Fig. 10A) is a fleshy muscle that originates on the cranio-dorsal aspect of the *carpometacarpus* (Fig. 8A) and inserts into a wide area of the medial aspect of the phalanx of the *digiti alulae* (Fig. 8A).

The *m. abductor digiti majoris* (Fig. 10A) has a fleshy origin on the *processus pisiformis* of the ventral surface of the *carpometacarpus* (Fig. 8A) and inserts into the proximal phalanx of the *digiti majoris* via a tendon (Fig. 8A).

The *m. flexor digiti minoris* (Fig. 10A) is a long and thin muscle that originates fleshy along the *os metacarpale minus* (Fig. 8A) and inserts into the proximal region of the phalanx of the *digiti minoris* via a tendon (Fig. 8A).

### Muscle mass

The total forelimb muscle mass represented between 7.68 and 10.26% of the body mass (Table 1). The *m. pectoralis* had the highest value of mass (~5 % of the body mass), whereas the remaining muscles had lower values, ranging between 0.01 and 0.79% (Table 1).

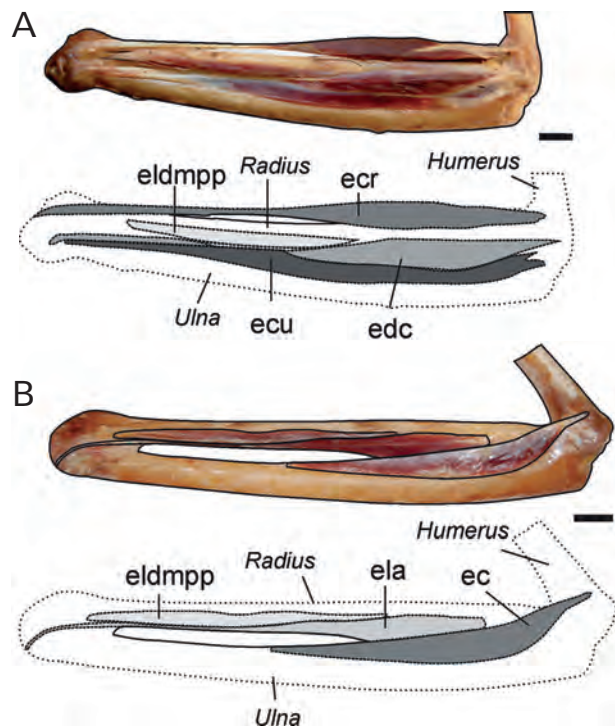


The muscles that move the *humerus* (*mm. scapulo-humeralis caudalis*, *deltoideus major* and *supratoracoideus*) and those that move the forearm and elbow (*mm. biceps brachii*, *humerotriceps* and *scapulotriceps*) had the highest values of muscle mass after the *m. pectoralis*, representing between 0.21 and 0.79% of the body mass (Table 1). Other humeral muscles, such as the *latissimus dorsii caudalis*, *coracobrachialis cranialis*, *subscapularis* and *subcoracoideus* showed values that ranged between 0.11 and 0.19 % of the body mass. The mass of the muscles involved in the downstroke represented between 6.73 and 7.56 % of the body mass, whereas the muscles involved in the upstroke represented between 0.21 and 1.22 % of the body mass (Table 1). Other muscles that had a considerable mass were those that act in the movements of the wrist and rotation of the forearm: the *flexor carpi ulnaris*, *extensor metacarpalis radialis* and *pronator profundus*, representing between 0.12 and 0.18% of the body mass (Table 1). The muscles that stabilize the thoracic shoulder (*mm. serratus* and *rhomboideus*) represented between 0.13 and 0.17 % (Table 1). The remaining muscles, i.e. those associated with the movements of the wrist and digits, represented a small portion of the body mass, ranging between 0.01 and 0.07%.

## Discussion

### Comparison with other Falconidae species

The forelimb myology of *Caracara plancus*, *Milvago chimango* and *Milvago chimachima* was similar to that described for *Falco sparverius* (MEYERS, 1992 a, 1996), *Polihierax semitorquatus* (BERGER, 1956), *Falco tinnunculus* (CANOVA *et al.*, 2015 a, b), and birds in general (e.g. GEORGE AND BERGER, 1966; RAIKOW, 1985). However, some specific differences can be identified with respect to *Falco* or *Polihierax*. The general morphology of the *m. pectoralis* was different from that of *Falco sparverius*. In caracaras, the *m. pectoralis* did not show the typical subdivisions as in *F. sparverius*, where this muscle has distinct deep muscular fascicle groups (MEYERS, 1992a; 1993). These deep muscular fascicles are involved in the gliding flight (MEYERS, 1993), commonly used by *F. sparverius* but not by caracaras. In the polyborines studied, single bellies were present in muscles like the *humerotriceps* and *subcoracoideus*, whereas in *Falco sparverius* these muscles have two bellies (MEYERS, 1992a). BERGER (1956) described the *m. subcoracoideus* only in *P. semitorquatus*, being this similar to that here described for polyborines. The *mm. flexor carpi ulnaris* and *extensor longus alulae* of the polyborines studied presented a single belly in their origin, whereas those of *Polihierax semitorquatus* and *Falco sparverius* present two bellies (BERGER, 1956; MEYERS, 1996). In *Falco tinnunculus*, the *m. flexor carpi ulnaris* possesses three bellies (CANOVA *et al.*, 2015b). The *m. abductor alulae* of the polyborines



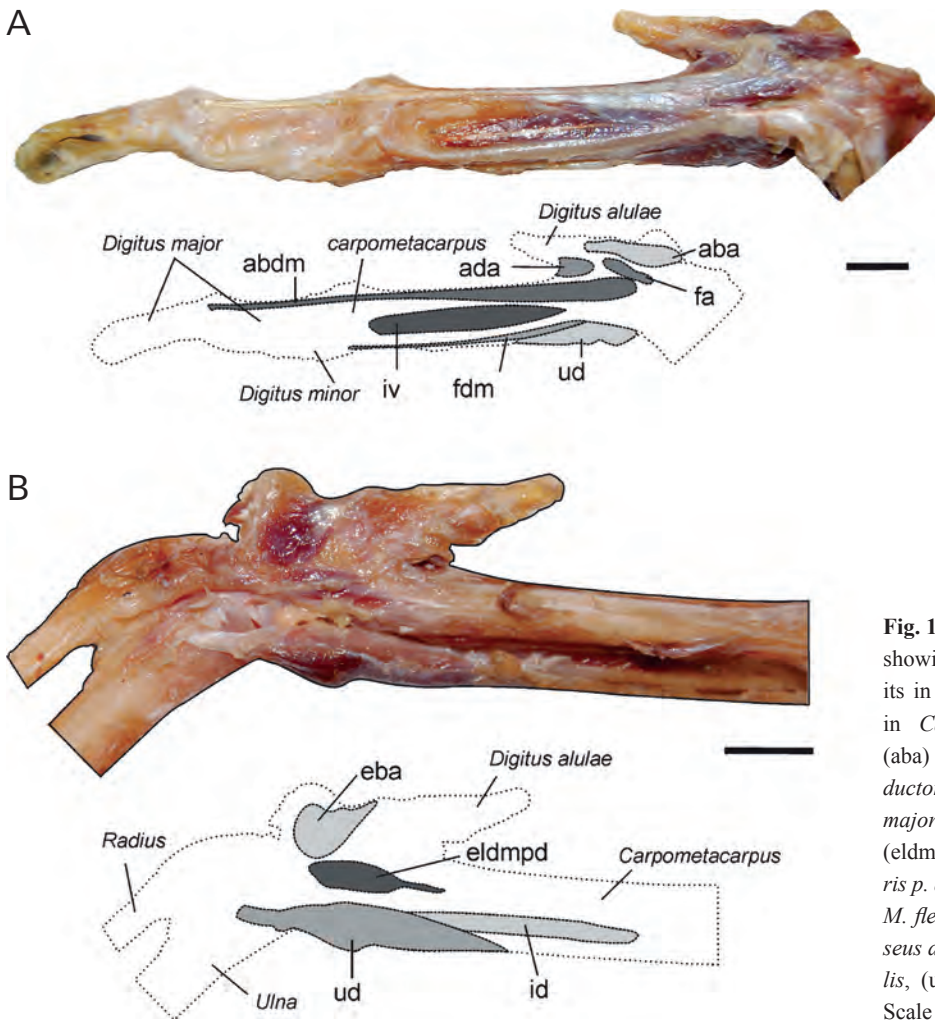
**Fig. 9.** Image and schematic drawings of the dorsal aspect of the forearm showing (A) superficial and (B) deep muscles in *Caracara plancus*. Abbreviations: (ec) *M. ectepicondylo-ulnaris* (ecr) *M. extensor carpi radialis*, (ecu) *M. extensor carpi ulnaris*, (edc) *M. extensor digitorum communis*, (ela) *M. extensor longus alulae*, (eldmpp) *M. extensor longus digiti majoris p. proximalis*. Scale bars: 1cm.

here studied presented two bellies, like in *Polihierax* (BERGER 1956), whereas that of *Falco sparverius* presents a single belly (MEYERS, 1996). The presence of accessory bellies in certain muscles is a modification that increases the number of fibers and, consequently, the physiological cross-section is also increased, producing a greater force (BOCK, 1974). Therefore, the occurrence of one muscular belly in muscles that move the *humerus* (*m. subcoracoideus*), extend the elbow (*m. humerotriceps*) and flex and extend the wrist (*m. flexor carpi ulnaris* and *m. extensor longus alulae*) in *Caracara* and *Milvago* could be associated with a more generalized mode of flight. Finally, the polyborines studied here presented no sesamoids in the tendons of the insertions of the *mm. flexor carpi ulnaris* and *extensor longus digiti majoris*, unlike that observed in *Falco sparverius*, which presents these sesamoids (MEYERS, 1996). The absence of sesamoids could be associated with less mechanical advantage with respect to the muscles with sesamoids (BERGER & STORER, 1995; SARIN *et al.*, 1999).

### Muscle mass

In the Polyborinae here studied, the wing muscle mass represented an important portion of the body mass (7.68 to 10.26 %), whereas in the polyborine species studied





**Fig. 10.** Image and schematic drawings showing the muscles of manus and digits in (A) ventral and (B) dorsal aspect in *Caracara plancus*. Abbreviations: (aba) *M. abductor alulae*, (ada) *M. adductor alulae*, (abdm) *M. abductor digiti majoris*, (eba) *M. extensor brevis alulae*, (eldmpd) *M. extensor longus digiti majoris p. distalis*, (fa) *M. flexor alulae*, (fdm) *M. flexor digiti minoris*, (id) *M. interosseus dorsalis*, (iv) *M. interosseus ventralis*, (ud) *M. ulnometacarpalis dorsalis*. Scale bars: 1cm.

by HARTMAN (1961) (*Caracara cheriway*) the values are slightly greater (11.61%). In *Falco sparverius*, the only Falconinae studied by HARTMAN (1961), the wing muscles represent a higher proportion of the body mass (29.92%), and the mass of the individual muscles (*pectoralis* and *supracoracoideus*) greatly exceeds that of those of the polyborines here studied. The relatively low values found in the muscle mass of caracaras could be associated with their less powerful flight, where flapping and gliding are alternated. Instead, the high values of *Falco sparverius* could be associated with the opposite situation: a flight characterized by fast flapping, with an ability to hover and stoop when a prey is caught (CANEVARI *et al.*, 1991; GRIN, 2018).

Most of the muscle mass of the wing is involved in the movements of the *articulatio omalis* (see Table 1); this joint has the greatest degree of mobility in the wing and its movements affect the entire limb (RAIKOW, 1985). The main *humerus* movements that produce the downstroke and upstroke, i.e. the two main phases of the flapping flight, are depression, elevation, protraction, retraction and rotation (DIAL *et al.* 1988). The downstroke provides the propulsive force required to generate both the lift and thrust (DIAL *et al.*, 1988; GOSLOW *et al.*, 1990), and, in caracaras, this is in accordance with the great muscle mass

dedicated to this movement. Instead, the upstroke prepares the wing for the next downstroke (DIAL *et al.*, 1988) and the relevant muscle mass is lower (see Table 1).

In the polyborines studied, the *m. pectoralis* was the largest muscle of the wing, a feature in accordance with its important functions during flight. This muscle acts during the downstroke, generating the lift and thrust required for flight and counteracting the inertia of the wing (DIAL, 1992; DIAL & BIEWENER, 1993; TOBALSKE, 2007). The second largest muscle of the polyborines studied was the *m. scapulohumeralis caudalis*, which is also a downstroke muscle. This muscle produces the retraction of the *humerus* and the ventral rotation of the wing, showing great activity (DIAL, 1992). Investigations in pigeons have established that the *m. supracoracoideus* (the primary upstroke muscle) is the second largest muscle in the wing (TOBALSKE, 2007; TOBALSKE & BIEWENER, 2008), but this does not hold true for caracaras. The significance of this difference remains to be studied in other birds with different styles of flight and/or phylogenetic relationship.

Besides the *mm. pectoralis* and *scapulohumeralis caudalis*, the muscles with the largest masses were the upstroke muscles *mm. deltoideus major* and *supracoracoideus*. Electromyographic data have indicated that the *m. deltoideus major* helps the *m. supracoracoideus* in the

elevation of the wing and that the *m. supracoracoideus* also elevates the *humerus* and contributes to decelerating the wing during the upstroke (DIAL, 1992). POORE *et al.* (1997) proposed that this muscle also produces the rotation of the *humerus*. It is difficult to assess the contribution of the remaining muscles to the *humerus* movements because they have not been studied with electromyographic techniques and, consequently, their roles in wing movements have only been inferred by their anatomical position (see RAIKOW, 1985; MEYERS, 1992a; 1998).

The other muscles with considerable mass were those involved in the movements of the forearm. The *m. biceps brachii*, in addition to flexing the forearm, is also a stabilizer of the elbow joint (together with the *m. humerotriceps*) during the final one-half of the downstroke (DIAL, 1992). The *m. scapulotriceps* also contributes to the stabilization of the elbow during flapping flight and the *m. humerotriceps* extends the elbow during descending flight (DIAL, 1992). The *m. pronator profundus* allows the rotation of the wing and is intensely active during takeoff and ascending flight (DIAL, 1992).

The movements of the wrist are performed by several muscles but only two of them showed relatively higher mass: the *mm. extensor metacarpi radialis* and the *flexor carpi ulnaris*. This is concordant with their important function, since these muscles are responsible for synchronized extension and flexion of the elbow and wrist joints (VAZQUEZ, 1994). Besides, the action of these muscles is intimately integrated with the “drawing-parallel” mechanism, i.e. the coordinated movements of the forearm and *manus* during the wing beat (for details see VAZQUEZ, 1994). Instead, the lowest mass values of the *mm. extensor digitorum communis*, *flexor digitorum superficialis* and *extensor metacarpi ulnaris* are in accordance with their poor contribution to the movements of the elbow and wrist (VAZQUEZ, 1994).

The small (or intrinsic) muscles that move the digits represented only a low percentage of the body mass. This could be related to the restriction in the movements of the *manus* during flight, which are subject to strong stresses (VAZQUEZ, 1995), and to the fact that it is generally proposed that these muscles contribute little to the mechanics of the flight (BIEWENER, 2011).

Other small muscles of caracaras like those located near the humeral joint (*mm. latissimus dorsi cranialis*, *deltoideus minor*, *scapulo humeralis cranialis* and *brachialis*) are involved in the postural control of the folded wing (MEYERS, 1992b).

## Conclusions and future directions

Although the wing muscles have a multifunctional nature that complicates the interpretation of their role during flight (VIDELER, 2006), this study highlights the utility of muscular mass data to understand and explore the possible importance of individual muscles or muscular groups

during this mode of locomotion. This is possible because the muscle mass is proportional to the maximum muscle power output (BIEWENER & ROBERTS, 2000; ROBERTS, 2001). Moreover, this kind of information, combined with quantitative information, like electromyographic, histochemical or muscular architectural data, may allow us to achieve an integrative assessment of the muscle function. The lack of similar works in birds prevents comparison and detailed analysis about how muscle mass can vary in birds with different flying styles. However, this analysis is a first step towards the exploration of this area of study.

## Acknowledgements

Thanks to Y. Davies (Museo Argentino de Ciencias Naturales Bernardino Rivadavia, MACN)

## References

- BAUMEL, J.J., KING, S.A., BREAZILE, J.E., EVANS, H.E. & BERGE, J.C. (1993): Handbook of Avian Anatomy, Nomina Anatomica Avium. Publication 23 of Nuttall Ornithological Club. Cambridge.
- BERGER, A.J. (1956): The appendicular myology of the Pygmy Falcon (*Polihierax semitorquatus*). – American Midland Naturalist, **55**: 326–333.
- BERGE, J.C. & STORER, R.W. (1995): Intratendinous ossification in birds: a review. – Journal of Morphology, **226**: 47–77.
- BIEWENER, A.A. (2011): Muscle function in avian flight: achieving power and control. – Philosophical Transactions of the Royal Society of London B, **366**, 1496–1506.
- BIEWENER, A.A. & ROBERT, T.J. (2000): Muscle and tendon contributions to force, work and elastic energy savings: a comparative perspective. – Exercise and Sport Sciences Reviews, **2803**: 99–107.
- BOCK, W.J. (1974): The avian skeletomuscular system. In: Farmer D. S., King J. R. (Eds.), Avian biology, vol. 4. Academic Press, London, 119–257 pp.
- CADE, T.J. & DIGBY, R.D. (1982): The falcons of the world. Cornell University Press, New York.
- CANEVARI, M., CARRIZO, G.R., CANEVARI, M. & CANEVARI, P.C. (1991): Nueva guía de las aves argentinas. Fundación Acindar, Buenos Aires.
- CANOVA, M., BEDONI, C., HARPER, V., RAMBALDI, A.M., BOMBARDI, C. & GRANDIS, A. (2015a): Anatomical study of the musculus deltoideus and musculus flexor carpi ulnaris in 3 species of wild birds. – Veterinaria Italiana, **52**: 37–44.
- CANOVA, M., BEDONI, C., HARPER, V., BARAZZONI, A.M., DE FAVERI, A. & GRANDIS, A. (2015b): Anatomical differences in three wing muscles of the Grey heron (*Ardea cinerea*), the Common buzzard (*Buteo buteo*) and the Common kestrel (*Falco tinnunculus*): a possible functional interpretation. – Rivista Italiana di Ornitologia, **85**: 15–22.
- CANOVA, M., CLAVENZANI, P., BOMBARDI, C., MAZZONI, M., BEDONI, C. & GRANDIS, A. (2015c): Anatomy of the shoulder and arm mus-

- culature of the common buzzard (*Buteo buteo* Linnaeus, 1758) and the European honey buzzard (*Pernis apivorus* Linnaeus, 1758). – *Zoomorphology*, **134**: 291–308.
- CORVIDAE, E.L., BIERREGAARD, R.O. & PETERS, S.E. (2006): Comparison of wing morphology in three birds of prey: Correlations with differences in flight behavior. – *Journal of Morphology*, **267**: 612–622.
- DIAL, K.P. (1992): Activity patterns of the wing muscles of the pigeon (*Columba livia*) during different modes of flight. – *Journal of Experimental Zoology, Part A, Ecological Genetics and Physiology*, **262**: 357–373.
- DIAL, K.P. & BIEWENER, A.A. (1993): Pectoralis muscle force and power output during different modes of flight in pigeons (*Columba livia*). – *Journal of Experimental Zoology*, **176**: 31–54.
- DIAL, K.P., KAPLAN, S.R., GOSLOW, G.E. & JENKINS, F.A. (1988): A functional analysis of the primary upstroke and downstroke muscles in the domestic pigeon (*Columba livia*) during flight. – *Journal of Experimental Zoology*, **134**: 1–16.
- DUNNING, J.B. (2008): *Handbook of avian body masses*. Boca Raton, CRC Press.
- FUCHS, J., JOHNSON, J.A. & MINDELL, D.P. (2012): Molecular systematics of the caracaras and allies (Falconidae: Polyborinae) inferred from mitochondrial and nuclear sequence data. – *Ibis*, **154**: 520–532.
- GEORGE, J.C. & BERGER, A.J. (1966): *Avian Myology*. Academic Press, New York.
- GOSLOW, G.E., DIAL, K.P. & JENKINS, F.A. (1990): Bird flight: insights and complications. – *Bioscience*, **40**: 108–115.
- GRIN Global Raptor Information Network. (2018): Species account. Available at: <http://www.globalraptors.org/grin/indexAlt.asp>.
- HACKETT, S.J., KIMBALL, R.T., REDDY, S., BOWIE, R.C., BRAUN, E.L., BRAUN, M.J. et al. (2008): A phylogenomic study of birds reveals their evolutionary history. – *Science*, **320**: 1763–1768.
- HARTMAN, F.A. (1961): Locomotor mechanisms of birds. – *Smithsonian Miscellaneous Collections*, **143**: 1–91.
- HEERS, A.M., BAIER, D.B., JACKSON, B.E., & DIAL, K.P. (2016): Flapping before flight: high resolution, three-dimensional skeletal kinematics of wings and legs during avian development. – *PloS one*, **11**: e0153446.
- HERTEL, F., MALDONADO, J.E. & SUSTAITA, D. (2015): Wing and hindlimb myology of vultures and raptors (Accipitriformes) in relation to locomotion and foraging. – *Acta Zoologica*, **96**: 283–295.
- JARVIS, E.D., MIRARAB, S., ABERER, A.J., LI, B., HOUE, P., LI, C. et al. (2014): Whole-genome analyses resolve early branches in the tree of life of modern birds. – *Science* **346**: 1320–1331.
- JOLLIE, M.T. (1977): A contribution to the morphology and phylogeny of the Falconiformes. – *Evolutionary theory*, **3**: 1–141.
- LIVEZEY, B.C. & ZUSI, R.L. (2006): Higher-order phylogeny of modern birds (Theropoda, Aves: Neornithes) based on comparative anatomy: 1. Methods and characters. – *Bulletin of the Carnegie Museum of Natural History*, **37**: 1–544.
- MEYERS, R.A. (1992a): Morphology of the shoulder musculature of the American kestrel, *Falco sparverius* (Aves), with implications for gliding flight. – *Zoomorphology*, **112**: 91–103.
- MEYERS, R.A. (1992b): The morphological basis of folded wing posture in the American kestrel, *Falco sparverius*. – *Anatomical Record*, **232**: 493–498.
- MEYERS, R.A. (1993): Gliding flight in the American kestrel (*Falco sparverius*): an electromyographic study. – *Journal of Morphology*, **215**: 213–224.
- MEYERS, R.A. (1996): Morphology of the antebrachial musculature of the American kestrel, *Falco sparverius* (Aves). – *Annales of Anatomy*, **178**: 49–60.
- MOSTO, M.C., CARRIL, J. & PICASSO, M.B.J. (2013): The hindlimb myology of *Milvago chimango* (Polyborinae, Falconidae). – *Journal of Morphology*, **274**: 1191–1201.
- MOSTO, M.C., PICASSO, M.B.J. & BIONDI, L.M. (2016): Long-legged caracaras: terrestrial habitat and hindlimb morphology. – *Journal of Zoology*, **298**: 274–284.
- POORE, S.O., SANCHEZ-HAIMAN, A., & GOSLOW JR, G.E. (1997): Wing upstroke and the evolution of flapping flight. – *Nature*, **387**: 799–802.
- PRUM, R.O., BERV, J.S., DORNBURG, A., FIELD, D.J., TOWNSEND, J. P., LEMMON, E.M. & LEMMON, A.R. (2015): A comprehensive phylogeny of birds (Aves) using targeted next-generation DNA sequencing. – *Nature*, **526**: 569–577.
- RAIKOW, R.J. (1985): Locomotor system. In: King, A.S., McLelland, J. (Eds), *Form and Function in Birds*, vol. 3. Academic Press, London, 57–147pp.
- ROBERTS, T.J. (2001): Muscle force and stress during running in dogs and wild turkeys. – *Bulletin of the Museum of Comparative Zoology*, **156**: 283–295.
- SARIN, V.K., ERICKSON, G.M., GIORI, N.J., BERGMAN, A.G. & CARTER, D.R. (1999): Coincident development of sesamoid bones and clues to their evolution. – *Anatomical Record*, **257**: 174–180.
- SUSTAITA, D. (2008): Musculoskeletal underpinnings to differences in killing behavior between North American accipiters (Falconiformes: Accipitridae) and falcons (Falconidae). – *Journal of Morphology*, **269**: 283–301.
- TOBALSKE, B.W. (2007): Biomechanics of bird flight. – *Journal of Experimental Biology*, **210**: 3135–3146.
- TOBALSKE, B.W. & BIEWENER, A.A. (2008): Contractile properties of the pigeon supracoracoideus during different modes of flight. – *Journal of Experimental Biology*, **211**: 170–179.
- VAZQUEZ, R.J. (1994): The automating skeletal and muscular mechanisms of the avian wing (Aves). – *Zoomorphology*, **114**: 59–71.
- VAZQUEZ, R.J. (1995): Functional anatomy of the pigeon hand (*Columba livia*): a muscle stimulation study. – *Journal of Morphology*, **226**: 33–45.
- VIDELER, J.J. (2006): *Avian flight*. Oxford University Press, New York.
- WHITE, C.M., OLSEN, P.D. & KIFF, L.E. (1994): Family Falconidae (falcons and caracaras). In: Del Hoyo, J., Elliott, A., Sargatal, J. (Eds.), *Handbook of the birds of the World*, vol. XX Lynx Editions Barcelona, 216–277pp.